# The Lymphatic Anatomy of the Lower Eyelid and Conjunctiva and Correlation with Postoperative Chemosis and Edema

Sajna Shoukath, B.Med.Sci., M.B.B.S.
G. Ian Taylor, A.O., F.R.A.C.S.
Bryan C. Mendelson, F.R.C.S.E., F.R.A.C.S., F.A.C.S.
Russell J. Corlett, F.R.A.C.S.
Ramin Shayan, Ph.D., F.R.A.C.S.
Saam S. Tourani, M.B.B.S.
Mark W. Ashton, F.R.A.C.S.
*Melbourne, Toorak, and Fitzroy, Victoria, Australia*

**Background:** There are minimal data in the literature regarding the lymphatic drainage of the conjunctiva and lower eyelid and the relationship with postoperative chemosis and edema.
**Methods:** Injection, microdissection, and histologic and radiologic studies were conducted on 12 hemifacial fresh cadaver specimens. Indocyanine green lymphography was conducted in five volunteers.
**Results:** Histology identified lymphatic vessels superficial and deep to the orbicularis oculi. Cadaveric dissection, injection, and radiographic studies identified interconnecting superficial and deep facial lymphatic systems and a conjunctival lymphatic network draining through the tarsal plate to the deep lymphatic system. The superficial lymphatic collectors traveled in subcutaneous fat within the lateral orbital and nasolabial fat compartments. The lateral deep lymphatic collectors traveled beneath orbicularis oculi, then through the superficial orbicularis retaining ligament, and into the sub–orbicularis oculi fat in the roof of the prezygomatic space. These vessels descended to preperiosteal fat at the level of zygomaticocutaneous ligaments to travel adjacent to the facial nerve into preauricular nodes. Indocyanine green lymphography identified correlating draining pathways laterally to the parotid nodes and medially to submandibular nodes.
**Conclusions:** The authors have found that the lower eyelid and conjunctiva are drained by interconnecting superficial and deep lymphatic systems of the face. The superficial system is vulnerable to damage in incisions and dissection in the infraorbital area. The deep system is vulnerable to damage in dissection around the orbicularis retaining ligament and the zygomaticocutaneous ligaments. The authors suggest that concurrent damage to both the superficial and deep lymphatic systems, especially laterally, may be responsible for postoperative chemosis and edema. (*Plast. Reconstr. Surg.* 139: 628e, 2017.)

Persistent chemosis and edema of the lower eyelid is a well-recognized and, at times, distressing complication of periorbital surgery.[1–4] Historically, chemosis has been uncommon when raising skin flaps in this region, even when the underlying orbicularis muscle is included, and was more likely encountered with orbital floor approaches that involve full-thickness incisions between skin and periosteum, particularly those that paralleled the orbital margin and curved upward laterally.[3,5]

*From the Taylor Lab, Department of Anatomy and Neuroscience, University of Melbourne; Centre for Facial Plastic Surgery; and the O'Brien Institute Tissue Engineering Centre, Regenerative Surgery Group.*
*Received for publication December 1, 2015; accepted August 31, 2016.*
*Copyright © 2017 by the American Society of Plastic Surgeons*
DOI: 10.1097/PRS.0000000000003094

Ironically, chemosis had become an increasing problem associated with recent advances in surgical technique. In progressing from traditional simple skin redraping and tightening in blepharoplasty and face lifts to more comprehensive procedures involving lateral canthal support and orbicularis retaining ligament division and redraping for the upper midcheek, the published complication rates of persistent chemosis beyond 2 to 3 weeks have risen from 1 percent to 34.5 percent.[6,7]

The common factor in all of these procedures, both traditional and recent, has been deep surgery in the lateral canthal region that may have

**Disclosure:** *The authors have no financial interest to declare in relation to the content of this article.*



Copyright © 2016 American Society of Plastic Surgeons. Unauthorized reproduction of this article is prohibited.

Downloaded from http://journals.lww.com/plasreconsurg by 2FRmvMoSHs1UUfpMYa5b04sYVn/0foqQQ5ysIQGz0qdDfigE1NSeW+7os5uHaeK853AM3SJRMMBywBoz5WcC5/+ZzTdMsvSjvBFoc1lwkB8sf28YNJeuvBmLl42suUQlB0hGOOaKV0DNIXBtOnhq8hSZdwRJFsqJOGPoAzi72to= on 11/12/2023

Downloaded from http://journals.lww.com/plasreconsurg by 2FRmvMoSHs1UUfpMYa5b04sYVn/0foqQQ5ysIQGz0qdDfigE1NSeW+7os5uHaeK853AM3SJRMMBywBoz5WcC5/+ZzTdMsvSjvBFoc1lwkB8st28YNJeuvBmLl42suUQlB0hGOOaKV0DNIXBtOnhq8hSZdwRJFsqJOGPoAzi72ro= on 11/12/2023

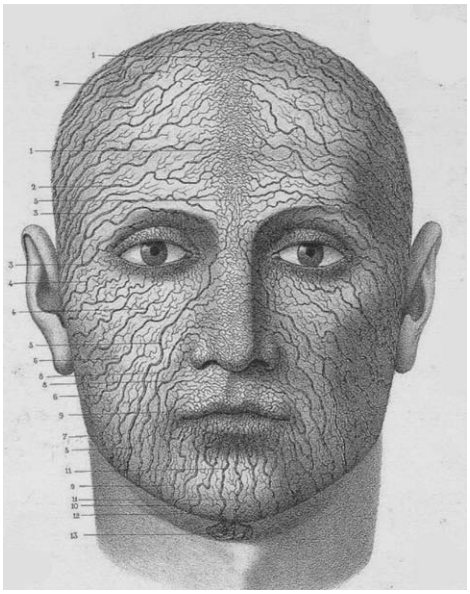

**Fig. 1.** Sappey's illustration of the superficial lymphatic network of the skin of the head and neck. Note the dominant lateral drainage of the eyelid except for a large collector draining the medial quadrants that parallel the facial vein on each side. (Reproduced from Sappey MPC. *Anatomie, physiologie, pathologie des vaisseaux lymphatiques considérés chez l'homme et les vertébrés*. Paris: Adrien Delahaye; 1874.)

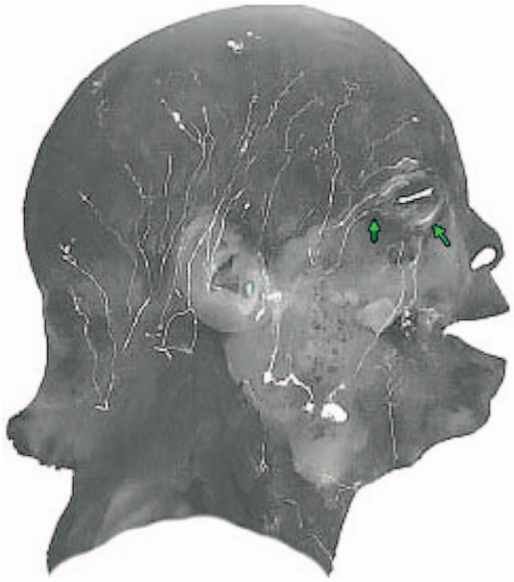

**Fig. 2.** One of our archival studies of the superficial tissues of the head and neck with *green arrows* highlighting the drainage of the eyelids to the preauricular and submandibular lymph nodes. (Reproduced from Pan WR, Suami H, Taylor GI. Lymphatic drainage of the superficial tissues of the head and neck: Anatomic study and clinical implications. *Plast Reconstr Surg*. 2008;121:1614–1624.)

interrupted the lymphatic drainage of the region. Although a superficial collecting lymphatic system of the eyelids was well described over 100 years ago by Sappey[8] (Fig. 1), dominant laterally and confirmed in our earlier lymphatic studies[9,10] (Fig. 2), a deep system draining the conjunctiva and eyelids was not defined.

Although a deep collecting lymphatic system has been suggested by previous histologic and ink injection studies,[11–17] there has not been a detailed study demonstrating a deep pathway draining the conjunctiva and connecting with the lymphatics of the eyelids and face. This study sets out to explore this void in our knowledge.

## MATERIALS AND METHODS

The study has three components: (1) histologic examination of cadaveric eyelid tissue; (2) cadaveric dissection and injection of lymphatic vessels; and (3) clinical correlation using near-infrared fluorescent imaging with indocyanine green injection. Ethics approval was granted for all components of the study (University of Melbourne Human Ethics Advisory Group number 1340286.1 and Human Research Ethics Committee number 1442614). Written consent was obtained from participants in the third section of the study.

### Histology

#### Methods

Histology was used to define the structure of the subcutaneous tissues of the eyelid and cheek to locate the lymphatic vessels in these layers, and thereby to target dissection of these areas in cadaver specimens. Six full-thickness fresh cadaver sections were taken from the lower eyelid at the lateral canthus, the midpoint, and at the medial canthus, extending down to the cheek. Samples were either fixed in 10% formalin and stained with hematoxylin and eosin or sent for immunohistochemistry staining with anti-human podoplanin (D2-40), a marker expressed on the lymphatic endothelium of all subtypes of lymphatic vessels.[18]

#### Results

The hematoxylin and eosin–stained sections revealed a structure similar to previous descriptions[19,20] of the subcutaneous tissues of the face, with three layers found within the eyelid and five layers in the cheek (Fig. 3). Based on our previous studies[20] of lymphatic drainage of the limbs in which we found lymphatic collecting vessels in the subcutaneous fat (layer 2C) and in layer 4, deep to the superficial fascia, we hypothesized that a similar pattern of collecting lymphatic vasculature



Copyright © 2016 American Society of Plastic Surgeons. Unauthorized reproduction of this article is prohibited.

Downloaded from http://journals.lww.com/plasreconsurg by 2FRmvMoSHs1UUfpMYa5b04sYVn/0foqQQ5ysIQGz0qdI dfigE1NSeW+7os5uHaeK853AM3SJRMMBywBoz5WcC5/+ZzTdMsvSjvBFoc1lwkB8st28YNJeuvBmLl42suIUQlB0hGOOaKV0DNIXB tOnhq8hSZdwRJF5qJOGP0AzI72to= on 11/12/2023

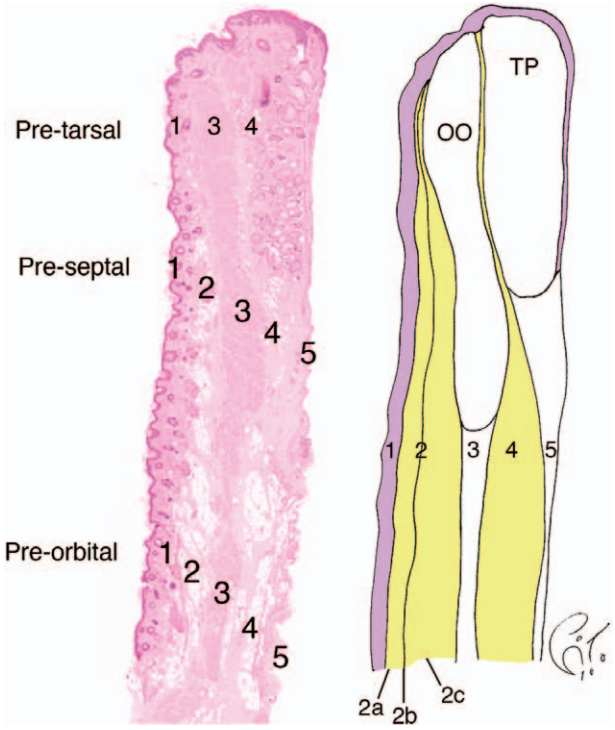


**Fig. 3.** (*Left*) Hematoxylin and eosin–stained vertical section of the lower eyelid showing the five layers of the subcutaneous tissue: *1*, skin; *2*, subcutaneous fat; *3*, orbicularis oculi (superficial fascia/superficial musculoaponeurotic system); *4*, sub–orbicularis oculi fat; and *5*, deep fascia/periosteum. The subcutaneous fat (layer 2) is further subdivided by a thin fascial layer 2B (shown in Figure 5) into layer 2A (fat), 2B (fascia), and 2C (fat). (*Right*) Schematic diagram of the same section highlighting the layers of the subcutaneous tissue. *OO*, orbicularis oculi; *TP*, tarsal plate.

would be found in the face. Immunohistochemical analysis supported this hypothesis, with vessels that exhibited positive D2-40 staining found both superficial and deep to the orbicularis oculi in the lower eyelid (Fig. 4).

### Cadaveric Dissection and Injection Studies

Cadaveric dissection, injection, and radiographic studies were targeted to identify the lymphatic network of the conjunctiva and its connection to the facial lymphatic system. Having identified the superficial collecting lymphatic drainage system of the face previously,[9] we set out to search for the as yet undescribed deep drainage system, which we hypothesized would be present below layer 3 (superficial musculoaponeurotic system) as in other parts of the body.[20]

#### Methods

Twelve hemifacial specimens were studied from six fresh cadavers and were combined with 32 head and neck archival studies performed in our unit.[9,10] Hydrogen peroxide was used to identify the lymphatic vessels as described previously.[21] The lymphatic vessels were dissected and photographed under a surgical microscope (Surgical Microscope; Zeiss, Nato Technology Systems Division, Oberkochen, Germany). Suitable vessels were injected with a lead oxide mixture consisting of 5 g of lead oxide, 1 g of milk powder, and 100 ml of boiling water. For injections, 33-gauge, ½-inch needles (Steriject Needle; TSK Laboratory, Tochigi-Ken, Japan) mounted on extension tubes attached to 1-ml syringes were used. Injected vessels were dissected under the surgical microscope and photographed using a mounted Nikon digital camera (Nikon, Tokyo, Japan) microscopically and a Canon EOS 600D with either a macro lens (Canon EF 100 mm f/2.8L Macro; Canon, Tokyo, Japan) or a wide-angle lens (Canon EF 50 mm f/1.8L). Radiographs (Fuji FCR IP Cassette and Fuji Computed Radiography Processor; Fuji Film Corp., Tokyo, Japan) of injected specimens were taken following dissection after removal from the facial skeleton.

Six hemifacial specimens from three cadavers were removed subperiosteally and superficial to the masseter without the globe to study the lymphatic drainage of the eyelids and cheek. Sharp dissection commenced at the lateral canthus, medial canthus, and midway between focusing on layer 2C in the subcutaneous fat, superficial to the orbicularis oculi, where lymphatic collectors were found as expected (Fig. 5). In contrast to the extremities, there was a paucity of valves. Because of the regurgitant flow of the lead oxide mixture within vessels, multiple injections were required to trace the pathways of the collectors to their destination.

In another six hemifacial specimens, the lymphatic drainage of the conjunctiva was studied in situ with the tissue still attached to the skull. Hydrogen peroxide was dripped onto the surface of the conjunctiva and injected beneath the Tenon capsule to identify lymphatic precollectors that, when injected, filled a fine lattice of capillaries across the eyeball but stopped at the tarsal plate. The eyelid was split and these pathways were traced through the tarsal plate and thereafter beneath the orbicularis to their destination in the cheek.

#### Results

The cadaveric studies identified a lymphatic network of avalvular capillaries (<0.05 mm) originating in the conjunctiva and draining to precollectors that passed through the tarsal plate and



Copyright © 2016 American Society of Plastic Surgeons. Unauthorized reproduction of this article is prohibited.

Downloaded from http://journals.lww.com/plasreconsurg by 2FRmvMoSHs1UUfpMYa5b04sYVn/0foqQQ5ysIQGz0qdd/figE1NSeW+7os5uHaeK853AM3SJRMMBywBoz5WcC5/+ZzTdMsvSjvBFoc1lwkB8sf28YNJeuvBmLl42suUQlB0hGOOaKV0DNIXBtOnhq8hSZdwRJFsqJOGPoAzi72to= on 11/12/2023

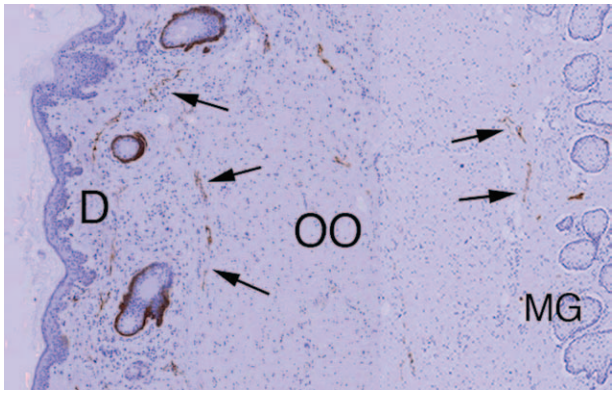


**Fig. 4.** Immunohistochemical staining of a vertical section of the lower eyelid with anti-human podoplanin D2-40. Lymphatic vessels (*arrows*) are stained brown and appear both superficial and deep to the orbicularis oculi (*OO*). The dermis (*D*) and Meibomian glands (*MG*) in the eyelid cartilage are indicated.

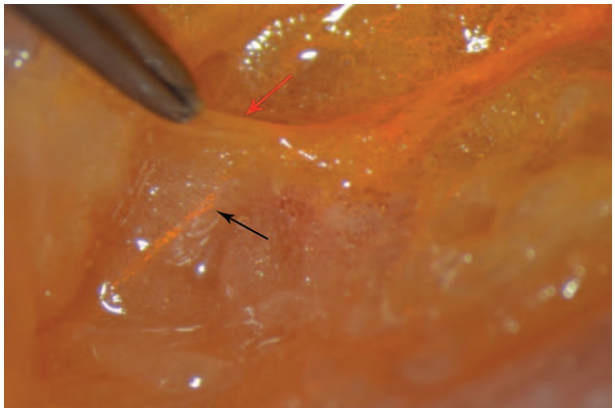

**Fig. 5.** Injected superficial lymphatic collector (*black arrow*) coursing in subcutaneous fat (layer 2C) beneath the fine fascial layer 2B (*red arrow*) that has been lifted up with forceps (compare with Fig. 3, *right*).

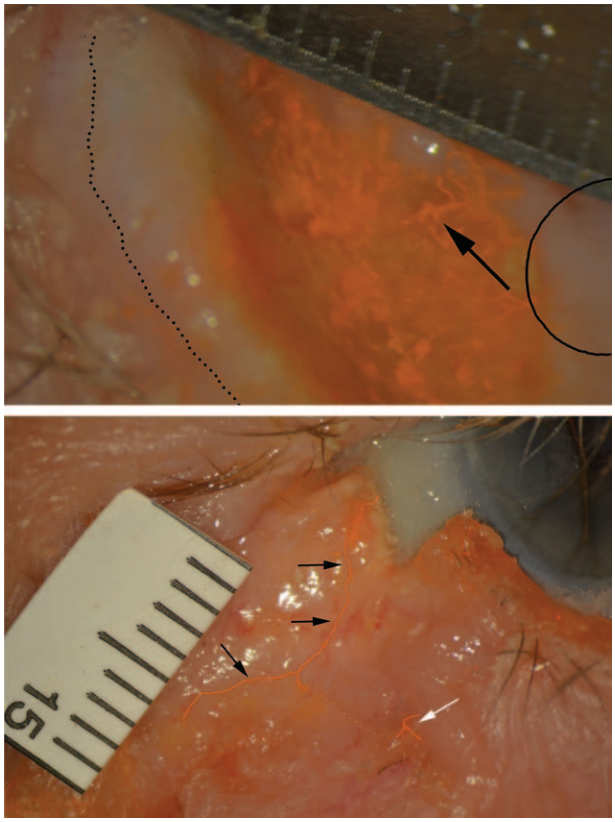


**Fig. 6.** (*Above*) Lead oxide injection of the lower lateral conjunctiva of the right eye showing the avalvular interconnecting network of lymphatic capillaries. The gray line of the eyelid is indicated by a *dotted line* and the cornea is indicated by a *black circle*. (*Below*) The lower eyelid tarsal plate of the right eye has been divided adjacent to the lateral canthus showing an injected precollector (*black arrows*, highlighted in *orange*) passing through at the site of the Meibomian glands to travel deep to the orbicularis oculi with connections through the muscle (*orange dotted line*) to the injected precollector (*white arrow*) superficial to the muscle.

Meibomian gland "porthole" weak points in the lateral third of the lid to join the superficial and deep collecting lymphatic systems of the face (Fig. 6).

The superficial lymphatic system drained the eyelids and was dominant laterally, as we have described previously.[10] The deep lymphatic system drained the conjunctiva and connected with the superficial lymphatic system through the preseptal orbicularis muscle. There was a paucity of valves in the lymphatic collecting vessels, similar to the venous system of the head and neck[22] but in contrast to the lower limb. We found that the lymphatic pathways draining the face may also parallel the neurovascular system, with medial lymphatic vessels following the facial vein and lateral lymphatic vessels running adjacent to the facial nerve and vessels.

*Superficial Lymphatic System.* The superficial lymphatic system of the face drained the conjunctiva and skin, with precollectors (0.05 to 0.1 mm) forming in the dermis near the medial and lateral canthi. These went on to form collecting lymphatic vessels (>0.1 mm) superficial to the preseptal orbicularis oculi at the level of the lateral and medial thirds of the orbicularis retaining ligament. These collecting lymphatics traveled within the subcutaneous fat of the cheek (layer 2C) under the thin membranous layer 2B. Each of these vessels stayed within a discrete fat compartment, the medial within the nasolabial fat compartment and the lateral within the lateral orbital fat compartment (Fig. 7). Lateral and medial collecting systems drained toward preauricular and submandibular nodes, respectively. In addition, the superficial system had connections to



Copyright © 2016 American Society of Plastic Surgeons. Unauthorized reproduction of this article is prohibited.



**Fig. 7.** Pathways of the superficial lymphatic collector draining the lateral (*left*) and medial (*right*) areas of the right lower eyelid toward the preauricular and submandibular lymph nodes, respectively. Collectors are highlighted in *orange* and the pathway indicated by *red arrows*.

Downloaded from http://journals.lww.com/plasreconsurg by 2FRmvMoSHs1UUfpMYa5b04sYVn/0foqQQ5ysIQGz0qdd/figE1NSeW+7os5uHaeK853AM3SJRMMBywBoz5WcC5/+ZzTdMsvSjvBFoc1lwkB8sf28YNJeuvBmLl42suUQlB0hGOOaKV0DNIXBtOnhq8hSZdwRJFsqJOGPoAzi72to= on 11/12/2023

the deep drainage system, with precollectors traveling through dermis and fibers of the preseptal orbicularis muscle to join the deep system.

*Deep Lymphatic System.* The deep lymphatic system of the face drained the conjunctiva directly from precollectors traveling through the tarsal plate and Meibomian glands in the lateral third of the lower eyelid. The deep lymphatic system was joined by connections with the superficial lymphatic system from the skin of the eyelid and face as described above.

Lymphatic precollectors of the deep system then traveled *beneath* the surface of the preseptal orbicularis in the lateral lower quadrant to the junction of the orbicularis retaining ligament and the lateral orbital thickening, traveling through the superficial orbicularis retaining ligament and enlarging to collecting vessels that traveled in the sub–orbicularis oculi fat in the roof of the prezygomatic space (Fig. 8, *above*). At the level of the most cranial zygomaticocutaneous ligaments, the collecting vessels descended to preperiosteal fat, from which the zygomaticus major arose, and then descended beneath deep fascia to travel adjacent to the facial nerve to reach the preauricular lymph nodes within the parotid (Fig. 8, *below*).

An equivalent medial deep facial lymphatic system was not identified despite extensive attempts to locate it. Given histologic evidence of deep lymphatic vessels in the medial eyelid, it is probable that this system also exists but may be smaller or less developed than the lateral system.

## Near-Infrared Fluorescence Imaging

### Methods

Clinical correlation with cadaver dissections was conducted through the use of near-infrared fluorescence imaging using indocyanine green injections and a PhotoDynamic Eye Lymphatic Camera (H*amamatsu* Photonics K.K., *Hamamatsu*, Japan). Near-infrared imaging with indocyanine green is now a well-established method for identifying cutaneous lymphatics[20] and is used commonly in lymphatic surgery and lymphedema treatment.[23]

Five healthy volunteers (two female and three male volunteers) were injected intradermally with 0.05 ml of 5 mg/ml indocyanine green in either a lateral or medial position on the lower eyelid, superior to the orbital rim. Gentle lymphatic massage was performed for 1 minute to encourage propagation of the indocyanine green. Video images were recorded at 5-minute intervals for 30 minutes to track the drainage pathways of the indocyanine green.

### Results

The indocyanine green injections had a close correlation with the patterns found in cadaver dissection. Lateral collecting vessels drained to



Copyright © 2016 American Society of Plastic Surgeons. Unauthorized reproduction of this article is prohibited.

the preauricular and jugular-digastric nodes and medial collectors drained to the submandibular nodes (Fig. 9, *above* and *center*).

The initial lymphatic vessels were noted to be very fine in the area of the injection and probably correlated with lymphatic capillaries or small precollectors. Connections were noted between the medial and lateral collecting vessels, suggesting that the middle of the cheek is a watershed area that may drain to either pathway. As the indocyanine green traveled along the lymphatics, the pathway became noticeably larger, although less well defined, in keeping with the increased depth of the vessel from the skin surface.

In one subject, a circular connection between upper and lower eyelid precollectors was shown, demonstrating an absence of valves in this region (Fig. 9, *below*). All drainage from this connection eventually traveled caudally along a lateral pathway, suggesting that the *majority* of drainage of the eyelids is in this direction.

## DISCUSSION

Persistent lower eyelid edema has long been a problem following infraorbital incisions and dissection of subcutaneous fat. Over the past two decades, in addition to lower eyelid edema, increasing rates of persistent chemosis (edema

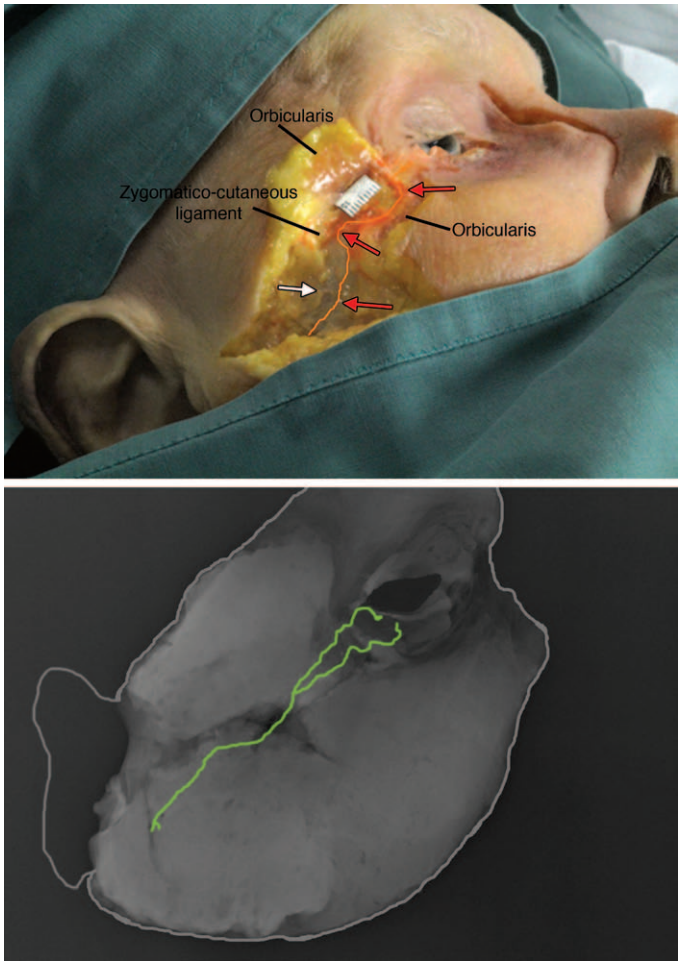


**Fig. 8.** (*Above*) The pathway of an injected deep lymphatic collector (*red arrows*, highlighted in *orange*) of the right hemiface, paralleling the branches of the facial nerve (*white arrow*) before entering the parotid gland. Note that the collector travels deep to the orbicularis oculi muscle and increases depth at the level of the zygomatico-cutaneous ligament. (*Below*) Radiograph of the specimen with the deep lymphatic pathway highlighted in *green*, beginning at the lower eyelid and traveling to the parotid gland.



Copyright © 2016 American Society of Plastic Surgeons. Unauthorized reproduction of this article is prohibited.

Downloaded from http://journals.lww.com/plasreconsurg by 2FRmvMoSHs1UUfpMYa5b04sYVn/0foqQQ5ysIQGz0qdd/igE1NSeW+7os5uHaeK853AM3SJRMMBywBoz5WcC5/+ZzTdMsvSjvBFoc1lwkB8sf28YNJeuwBmLl42suUQlB0hGOOaKV0DNIXBtOnhq8hSZdwRJFsqJOGPoAzi72to= on 11/12/2023

Downloaded from http://journals.lww.com/plasreconsurg by 2FRmvMoSHs1UUfpMYa5b04sYVn/0foqQQ5ysIQGz0qd dfigE1NSeW+7os5uHaeK853AM3SJRMMBywBoz5WcC5/+ZzTdMsvSjvBFoc1lwkB8sf28YNJeuvBmLl42suUQiB0hGOOaKV0DNIXB tOnhq8hSZdwRJFsqJOGPoAzi72ro= on 11/12/2023

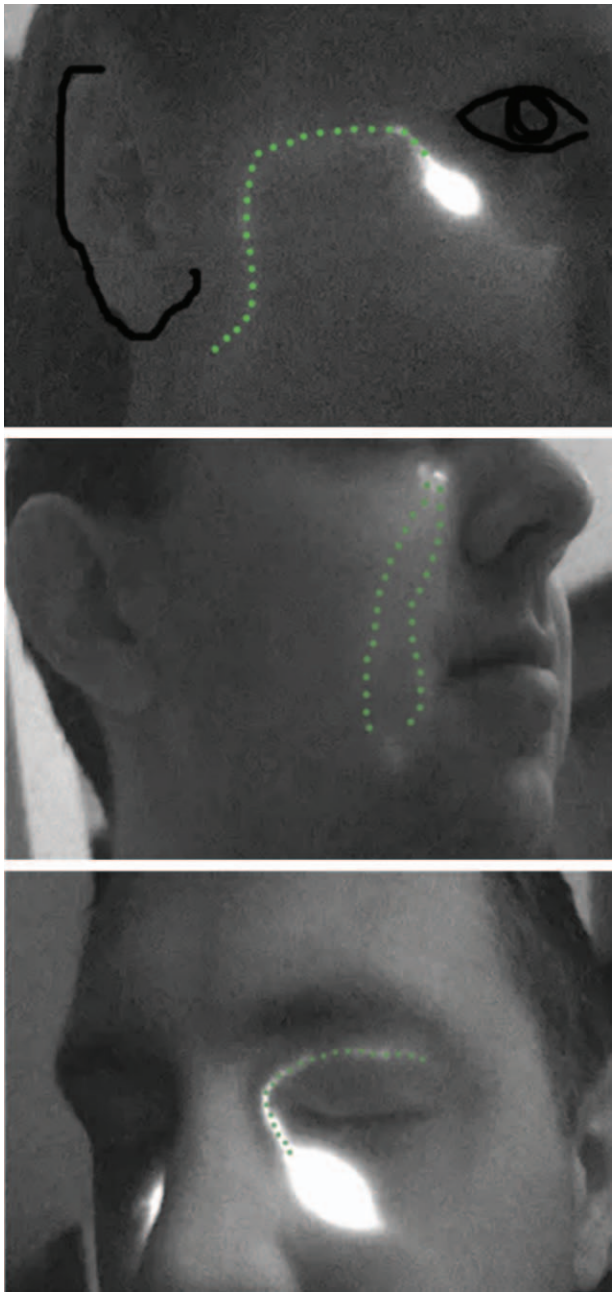

**Fig. 9.** Indocyanine green injections in vivo show the right lateral (*above*) and medial (*center*) lymphatic pathways draining to the preauricular and submandibular lymph nodes, respectively. (*Below*) Retrograde flow across the left upper eyelid in a separate study, demonstrating the avalvular vessels in this region.

of the conjunctiva) lasting longer than 2 to 3 weeks have been reported, particularly following lower eyelid blepharoplasty (Table 1). Although most cases of chemosis resolved within 2 to 3 months, some cases have persisted for up to 6 to 12 months.[24,25] Chronic cases of chemosis require treatments including steroid application, snip conjunctivoplasty, and radiowave electrosurgery[1,26,27] and is a far more significant complication than lower eyelid edema alone. Although the cause of postoperative chemosis is not well understood, it is considered to be a combination of postoperative inflammation and lymphatic dysfunction caused by surgical trauma.[1,25] Patients who have conjunctivochalasis or poor eyelid closure have also been noted to have a predisposition toward chemosis.[25]

Prolonged malar and lid swelling was first noted by Hamra[28] in his composite rhytidectomy technique in which much of the dissection was in the plane over the orbicularis oculi at the junction with subcutaneous fat. A study using lymphoscintigraphy has suggested that such extensive dissection during rhytidectomy may cause increased edema postoperatively by decreasing lymphatic outflow.[29] Increased rates of lower eyelid edema have been described[3] as incisions for orbital fracture fixation became more caudal and lateral on the face, which was attributed to damage to larger lymphatic vessels. Mendelson et al.[4] noted that excision of subcutaneous fat in malar mounds leads to prolonged swelling.

Our current study, and our archival injection studies,[10] support these observations. By combining the results of our three current investigations, we have shown a superficial lymphatic system composed of collecting vessels draining the skin of the lower eyelid. These formed superficial to the preseptal orbicularis muscle approximately 10 mm from the lid margin, in the region of the infraorbital incisions described above. These vessels also traveled within previously described subcutaneous fat compartments.[30]

Previous studies have reported that lymphatic collecting vessels take approximately 3 weeks to be reformed after injury,[31] and thus it can be expected that damage to these vessels will lead to prolonged lower eyelid and cheek edema while they are being repaired. In contrast, animal studies using fluorescent markers for lymphatic vessels have allowed the accurate study of healing capillary lymphatic vessels.[32] These studies have indicated that capillary vessels may commence sprouting as early as 5 days and form mature vessels 15 days after dermal wounding. It is likely that the reformation of the lymphatic vessels also prevents recurrence of chemosis once the initial lymphedema has been treated or has resolved.

However, the concept of a superficial lymphatic network being the only lymphatic pathway draining the lower eyelid failed to explain adequately the increasing rates of chemosis that accompany the more extensive deep dissection described in recent lower eyelid blepharoplasty.



Copyright © 2016 American Society of Plastic Surgeons. Unauthorized reproduction of this article is prohibited.

**Table 1. Reported Rates of Chemosis following Lower Eyelid Blepharoplasty**

| First Author, Year | Surgical Technique | No. of Patients | Chemosis Rate (%) |
|---|---|---|---|
| Seitz, 2012 | Transconjunctival, deep midface lift | 124 | 0.8 |
| Honrado, 2004 | Skin/muscle flap, suspension suture | 3988 | 1 |
| Maffi, 2011 | Skin/muscle flap, no canthopexy/plasty | 2007 | 1.2 |
| Prischmann, 2013 | Transconjunctival | 39 | 5.1 |
| Undavia, 2015 | Transconjunctival | 66 | 7.6 |
| Weinfeld, 2008 | Skin/muscle flap, release ORL, lateral canthopexy/plasty | 312 | 11.5 |
| Codner, 2008 | Skin muscle flap, release ORL, lateral canthopexy/plasty | 264 | 12.1 |
| Prischmann, 2013 | Skin muscle flap, lateral canthopexy | 694 | 34.5 |

ORL, orbicularis retaining ligament.

Downloaded from http://journals.lww.com/plasreconsurg by 2FRmvMoSHs1UUfpMYa5b04sYVn/0foqQQ5ysIQGz0qdDfigE1NSeW+7os5uHaeK853AM3SJRMMBywBoz5WcC5/+ZzTdMsvSjvBFoc1lwkB8sf28YNJeuvBmLl42suUQB0hGOOaKV0DNIXBtOnhq8hSZdwRJFsqJOGPoAzi72to= on 11/12/2023

In addition, if lymphatic drainage of the conjunctiva was dependant solely on a superficial network situated in the subcutaneous fat, chemosis should occur in any operation violating this layer, which we know to be untrue. Thus, there had to be a secondary deeper system of lymphatic drainage in the face that became more at risk as periorbital procedures involved more extensive lateral and deeper planes of dissection.

Our study has revealed this pathway. It has described for the first time and shown radiologically lymphatic vessels draining the conjunctiva by means of a deep network of collecting lymphatics in the face that has connections with the superficial network that we have described previously. The lymphatic capillaries of the conjunctiva joined the deep system by means of precollectors traveling through the tarsal plate laterally. The deep lymphatic collecting vessels formed deep to the preseptal orbicularis oculi at the level of the orbicularis retaining ligament's junction with the lateral orbital thickening. These vessels then coursed in the superficial portion of the orbicularis retaining ligaments to travel in the sub–orbicularis oculi fat in the roof of the prezygomatic space. At the level of the most cranial zygomaticocutaneous ligament, the vessels descended to the preperiosteal fat around the zygomaticus major origin and then traveled beneath the deep fascia adjacent to the facial nerve to drain into preauricular lymph nodes within the parotid (Figs. 10 and 11).

By scrutinizing the reported chemosis rates in various lower eyelid blepharoplasty techniques (Table 1), it becomes clear that the incidence of chemosis increases as the dissection in the procedure becomes deeper and more lateral. Skin-muscle flap lower eyelid blepharoplasty has a reported chemosis rate of 1 to 1.2 percent,[6,33] attributable to the minimal amount of dissection around the lateral canthus and the orbicularis retaining ligament. Transconjunctival access has rates of chemosis ranging from 0.8 to 7.6 percent[34,35] even when combined with deep dissection around the orbicularis retaining ligament, presumably because the superficial lymphatic network is not injured. It is notable that in both of these techniques, only one of the lymphatic systems of the face is potentially damaged. As the superficial and deep lymphatic systems of the face have interconnections through the preseptal orbicularis muscle, it is probable that damage to one system will be compensated for by the other without chemosis occurring.

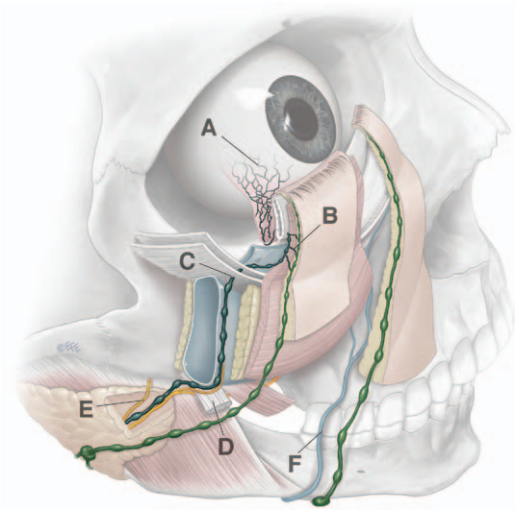


**Fig. 10.** Schematic diagram of the superficial and deep collecting lymphatic systems of the face. (Printed with permission ©EFE.) The deep lymphatic system (*dark green*) starts at the conjunctiva (*A*), pierces the tarsal plate and descends deep to the orbicularis, with connections through the muscle with superficial system (*B*). The vessels then travel through the superficial orbicularis retaining ligament (*C*) to run in sub–orbicularis oculi fat in the roof of the prezygomatic space. At the zygomaticocutaneous ligament (*D*), the vessels descend to preperiosteal fat and then follow branches of the facial nerve (*E*) to lymph nodes within the parotid. The superficial system (*light green*) drains the eyelid skin passing superficial to the orbicularis muscle with connections through the muscle with the deep system (*B*). Laterally it reaches preauricular lymph nodes and medially it parallels the path of the facial vein (*F*) to drain to mandibular and submandibular lymph nodes. The key points of potential obstruction of the lateral deep lymphatic system are at *C* and *D*.



Copyright © 2016 American Society of Plastic Surgeons. Unauthorized reproduction of this article is prohibited.

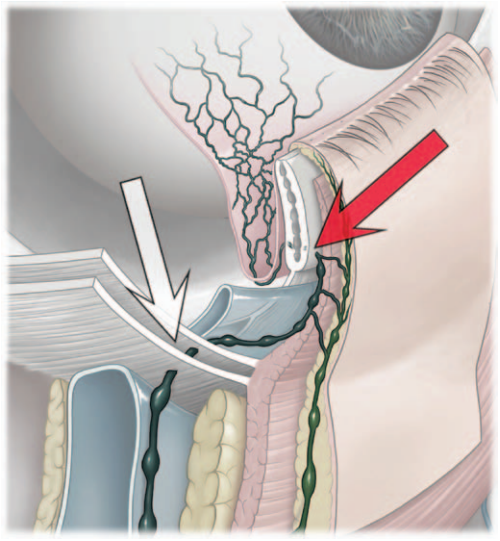

**Fig. 11.** Schematic diagram of the pathway of lymphatic vessels from the conjunctiva traveling through the tarsal plate at the level of the Meibomian glands (*red arrow*) and then on top of the preseptal space to travel through the superficial portion of the orbicularis retaining ligament (*white arrow*) and in the roof of the prezygomatic space.

However, when *both* the deep and the superficial systems are damaged, lymphatic outflow of the lower eyelid is severely compromised and relies on cross-connections with a potentially less developed medial drainage system. We propose that damage to the deep system, in addition to the superficial system, is the reason behind the increased chemosis rates of 11.5 to 34.5 percent in the series of lower eyelid blepharoplasty using lateral canthal support and redraping of the orbicularis retaining ligament.[1,2,7] We have documented that the deep system of lymphatics runs in close proximity to these structures. Anatomically, damage to the lateral collectors in these locations may cause lymphatic backflow through the valveless vessels in the watershed area in the middle of the cheek, thus depending on the medial lymphatic collectors alone.

## CONCLUSIONS

In addition to the previously described superficial system, our study has identified for the first time an important deep collecting lymphatic system of the midface. Because these lymphatic vessels have fewer valves than those in the limbs, they are predisposed to regurgitation and subsequent lymphedema from relatively minor obstruction caused by incisions, tight sutures, or kinking of vessels following surgery. We suggest that damage to the deep lymphatic system is more likely to occur with lateral deep dissection involving ligamentous supporting structure, especially of the lateral canthus, the lateral extent of the orbicularis retaining ligament, and the zygomaticocutaneous ligament. Concurrent injury to both deep and superficial lymphatic networks is likely responsible for prolonged chemosis postoperatively.

***Sajna Shoukath, B.Med.Sci., M.B.B.S.***
3/959 Rathdowne Street
Carlton North
Victoria 3054, Australia
shoukath.sajna@gmail.com

## REFERENCES

1. Weinfeld AB, Burke R, Codner MA. The comprehensive management of chemosis following cosmetic lower blepharoplasty. *Plast Reconstr Surg.* 2008;122:579–586.
2. Codner MA, Wolfli JN, Anzarut A. Primary transcutaneous lower blepharoplasty with routine lateral canthal support: A comprehensive 10-year review. *Plast Reconstr Surg.* 2008;121:241–250.
3. Bähr W, Bagambisa FB, Schlegel G, Schilli W. Comparison of transcutaneous incisions used for exposure of the infraorbital rim and orbital floor: A retrospective study. *Plast Reconstr Surg.* 1992;90:585–591.
4. Mendelson BC, Muzaffar AR, Adams WP Jr. Surgical anatomy of the midcheek and malar mounds. *Plast Reconstr Surg.* 2002;110:885–896; discussion 897.
5. Rohrich RJ, Janis JE, Adams WP Jr. Subciliary versus subtarsal approaches to orbitozygomatic fractures. *Plast Reconstr Surg.* 2003;111:1708–1714.
6. Honrado CP, Pastorek NJ. Long-term results of lower-lid suspension blepharoplasty: A 30-year experience. *Arch Facial Plast Surg.* 2004;6:150–154.
7. Prischmann J, Sufyan A, Ting JY, Ruffin C, Perkins SW. Dry eye symptoms and chemosis following blepharoplasty: A 10-year retrospective review of 892 cases in a single-surgeon series. *JAMA Facial Plast Surg.* 2013;15:39–46.
8. Sappey MPC. *Anatomie, physiologie, pathologie des vaisseaux lymphatiques considérés chez l'homme et les vertébrés.* Paris: Adrien Delahaye; 1874.
9. Pan WR, Suami H, Taylor GI. Lymphatic drainage of the superficial tissues of the head and neck: Anatomical study and clinical implications. *Plast Reconstr Surg.* 2008;121:1614–1624; discussion 1625.
10. Pan WR, Le Roux CM, Briggs CA. Variations in the lymphatic drainage pattern of the head and neck: Further anatomic studies and clinical implications. *Plast Reconstr Surg.* 2011;127:611–620.
11. Cook BE Jr, Lucarelli MJ, Lemke BN, et al. Eyelid lymphatics II: A search for drainage patterns in the monkey and correlations with human lymphatics. *Ophthal Plast Reconstr Surg.* 2002;18:99–106.
12. Guo W, Zhu Y, Yu PK, et al. Quantitative study of the topographic distribution of conjunctival lymphatic vessels in the monkey. *Exp Eye Res.* 2012;94:90–97.
13. Gusev AM. Lymph vessels of human conjunctiva. *Fed Proc Transl Suppl.* 1964;23:1099–1102.
14. Collin HB. Ocular lymphatics. *Am J Optom Arch Am Acad Optom.* 1966;43:96–106.
15. Clodius L, Földi M, Földi E, Kubik S. *Textbook of Lymphology.* 6th ed. Munich: Elsevier; 2005.



Copyright © 2016 American Society of Plastic Surgeons. Unauthorized reproduction of this article is prohibited.

Downloaded from http://journals.lww.com/plasreconsurg by 2FRmvMoSHs1UUfpMYa5b04sYVn/0foqQQ5ysIQGz0qdtOnhqBhSZdwRJFsqJOGPoAzi72to= on 11/12/2023
dfigE1NSeW+7os5uHaeK853AM3SJRMMBywBoz5WcC5/+ZzTdMsvSjvBFoc1lwkB8sf28YNJeuvBmLl42suIQlB0hGOOaKV0DNIXB

Downloaded from http://journals.lww.com/plasreconsurg by 2FRmvMoSHs1UUfpMYa5b04sYVn/0foqQQ5ysIQGz0qdtOnhq8hSZdwRJF5qJOGPoAzi72to= on 11/12/2023
dfigE1NSeW+7os5uHaeK853AM3SJRMMBywBoz5WcC5/+ZzTdMsvSjvBFoc1lwkB8sf28YNJeuvBmL142suUQB0hGOOaKV0DNIXB

16. Aglianó M, Lorenzoni P, Volpi N, et al. Lymphatic vessels in human eyelids: An immunohistological study in dermatochalasis and chalazion. *Lymphology* 2008;41:29–39.
17. Cook BE Jr, Lucarelli MJ, Lemke BN, et al. Eyelid lymphatics I: Histochemical comparisons between the monkey and human. *Ophthal Plast Reconstr Surg*. 2002;18:18–23.
18. Shayan R, Karnezis T, Murali R, et al. Lymphatic vessel density in primary melanomas predicts sentinel lymph node status and risk of metastasis. *Histopathology* 2012;61:702–710.
19. Mendelson B, Wong C. Anatomy of the ageing face. In: Warren RJ , Neligan PC, eds. *Plastic Surgery*. Vol. 2, 3rd ed. New York: Elsevier; 2012;78–92.
20. Tourani SS, Taylor GI, Ashton MW. Understanding the three-dimensional anatomy of the superficial lymphatics of the limbs. *Plast Reconstr Surg*. 2014;134:1065–1074.
21. Suami H, Taylor GI, Pan WR. A new radiographic cadaver injection technique for investigating the lymphatic system. *Plast Reconstr Surg*. 2005;115:2007–2013.
22. Taylor GI, Caddy CM, Watterson PA, Crock JG. The venous territories (venosomes) of the human body: Experimental study and clinical implications. *Plast Reconstr Surg*. 1990;86:185–213.
23. Mihara M, Hayashi Y, Hara H, et al. High-accuracy diagnosis and regional classification of lymphedema using indocyanine green fluorescent lymphography after gynecologic cancer treatment. *Ann Plast Surg*. 2014;72:204–208.
24. Pacella SJ, Codner MA. Minor complications after blepharoplasty: Dry eyes, chemosis, granulomas, ptosis, and scleral show. *Plast Reconstr Surg*. 2010;125:709–718.
25. McCord CD, Kreymerman P, Nahai F, Walrath JD. Management of postblepharoplasty chemosis. *Aesthet Surg J*. 2013;33:654–661.
26. Jones YJ, Georgescu D, McCann JD, Anderson RL. Snip conjunctivoplasty for postoperative conjunctival chemosis. *Arch Facial Plast Surg*. 2010;12:103–105.
27. Woo KI, Choi CY. High-frequency radiowave electrosurgery for persistent conjunctival chemosis following cosmetic blepharoplasty. *Plast Reconstr Surg*. 2014;133:1336–1342.
28. Hamra ST. Composite rhytidectomy. *Plast Reconstr Surg*. 1992;90:1–13.
29. Meade RA, Teotia SS, Griffeth LK, Barton FE. Facelift and patterns of lymphatic drainage. *Aesthet Surg J*. 2012;32:39–45.
30. Rohrich RJ, Pessa JE. The fat compartments of the face: Anatomy and clinical implications for cosmetic surgery. *Plast Reconstr Surg*. 2007;119:2219–2227; discussion 2228–2231.
31. Slavin SA, Upton J, Kaplan WD, Van den Abbeele AD. An investigation of lymphatic function following free-tissue transfer. *Plast Reconstr Surg*. 1997;99:730–741; discussion 742–743.
32. Shayan R, Karnezis T, Tsantikos E, et al. A system for quantifying the patterning of the lymphatic vasculature. *Growth Factors* 2007;25:417–425.
33. Maffi TR, Chang S, Friedland JA. Traditional lower blepharoplasty: Is additional support necessary? A 30-year review. *Plast Reconstr Surg*. 2011;128:265–273.
34. Seitz IA, Llorente O, Few JW. The transconjunctival deep-plane midface lift: A 9-year experience working under the muscle. *Aesthet Surg J*. 2012;32:692–699.
35. Undavia S, Briceño CA, Massry GG. Quantified incision placement for postseptal approach transconjunctival blepharoplasty. *Ophthal Plast Reconstr Surg*. 2016;32:191–194.



Copyright © 2016 American Society of Plastic Surgeons. Unauthorized reproduction of this article is prohibited.