

Tuberous Breast Deformity: Classification and Treatment Strategy for Improving Consistency in Aesthetic Correction

Adam R. Kolker, M.D.
Meredith S. Collins, M.D.

New York, N.Y.



Background: Tuberous breast deformity is a common congenital anomaly with varying degrees of constriction, hypoplasia, skin deficiency, areolar herniation, and asymmetry that poses challenges to consistency in aesthetic correction. In this study, the authors classify tuberous breast deformities, and evaluate their techniques used for treatment.

Methods: Twenty-six patients (51 breasts) treated from 2008 to 2012 were included. Mean patient age was 25 years (range, 18 to 39 years). Cases were classified using a three-tier system. A periareolar approach and glandular scoring maneuvers were used in all cases. Prosthetic placement (implant or tissue expander) was subpectoral (dual-plane) in all cases. The selection of one- versus two-stage correction and mastopexy techniques is presented with reference to the specific deformities in each tier.

Results: Mean follow-up was 22 months (range, 8 to 37 months). Twelve type I, 26 type II, and 13 type III deformities were treated. Periareolar incisions only were used in two (4 percent). Circumareolar mastopexy was used in 49 (96 percent), and vertical mastopexy was used in four (8 percent). One-stage correction was achieved in 47 (92 percent); four (8 percent) were treated in two stages with tissue expansion. The global complication rate for all patients in this study is 7.8 percent—two breasts (3.9 percent) had capsular contracture, and two (3.9 percent) had postoperative malposition.

Conclusion: The authors' experience demonstrates that satisfactory results can be obtained with appropriate classification and treatment of tuberous breast deformity with periareolar access, glandular scoring, subpectoral implant placement, and mastopexy techniques tailored to the specific deformity type. (*Plast. Reconstr. Surg.* 135: 73, 2015.)

CLINICAL QUESTION/LEVEL OF EVIDENCE: Therapeutic, IV.

The tuberous breast deformity is a congenital breast anomaly with widely varying degrees of presentation. Characteristics of the tuberous breast deformity include breast base constriction, parenchymal hypoplasia, inferior breast skin deficiency, superior malposition of the inframammary fold, areolar herniation, and asymmetry. Patients may present with one, several, or all of these anatomical hallmarks. These deformities are

widely variable, often with considerable discrepancies between both breasts in the same individual. The wide range of presentation, in conjunction with frequent asymmetry, poses great challenges to consistency in aesthetic correction.

Disclosure: *The authors have no commercial associations or financial interest to declare in relation to the content of this article. No external funding supported this study.*

From the Department of Surgery, Division of Plastic Surgery, Icahn School of Medicine at Mount Sinai.

Received for publication November 25, 2013; accepted April 23, 2014.

Presented at the 30th Annual Meeting of the Northeastern Society of Plastic Surgeons, in Washington, D.C., September 20 through 22, 2013.

Copyright © 2014 by the American Society of Plastic Surgeons

DOI: 10.1097/PRS.0000000000000823

Supplemental digital content is available for this article. A direct URL citation appears in the text; simply type the URL address into any Web browser to access this content. Clickable links to the material are provided in the HTML text of this article on the *Journal's* Web site (www.PRSJournal.com).

Nomenclature and classification are important in the preoperative identification of the presence and severity of each element, or combination of elements, to assist in achieving more consistent results. There have been several classification systems reported to define the spectrum of the tuberous breast deformity.¹⁻⁴ Meara and colleagues have previously described a three-tier classification⁴ that incorporated the specific pathologic hallmarks to aid in identification of the deformity and to establish a treatment strategy. In this article, we present an updated tuberous breast deformity classification system that has enabled the formulation of a surgical plan that can be tailored on an individual basis to all patients, and review our current principles and techniques for the aesthetic correction of tuberous breast deformity.

PATIENTS AND METHODS

Twenty-six patients (51 breasts) with a mean age of 25 years (range, 18 to 39 years) treated for tuberous breast deformity by the senior author (A.R.K.) from 2008 to 2012 were included and were reviewed in an institutional review board–approved retrospective study. Data collected included tuberous breast deformity classification, techniques used for correction, surgical outcome, and complications. Only patients with a minimum of 8 months of follow-up were included. As a measure of patient satisfaction, all patients who underwent tuberous breast correction were asked to complete a postoperative BREAST-Q quality-of-life outcomes questionnaire.⁵ Patient responses to four scales of the BREAST-Q reduction/mastopexy module were used: satisfaction with outcome, satisfaction with breasts, psychosocial well-being, and sexual well-being. Patient scores were converted into linearized measurements using the Q-score program⁶ and presented on a scale from 0 to 100. In addition, all patients’ postoperative photographs were graded by an independent plastic surgeon. Assessment was based on symmetry, breast shape, scar, and overall aesthetic

result. Postoperative results were graded as excellent, very good, good, or poor.

Classification Schema

We have used a three-tier classification system⁴ that facilitated our qualification of the anatomical considerations and severity of tuberous breast deformities. With further experience, we have updated the classification schema to better define the deformities and more appropriately tailor our treatment plans for each individual. To provide clarity in stratifying the pathologic condition and severity, we have maintained three tiers, but have further aided our approach to these deformities with the added descriptors for areolar herniation and ptosis. Details of the classification system are demonstrated in Table 1. The spectrum of anatomical variations by type is illustrated in Figure 1, and an example of the pathologic features of the deformity is shown in Figure 2.

Surgical Technique

Figure 3 demonstrates the treatment-planning algorithm used in this study. All patients are marked preoperatively in the upright position. Pertinent markings include the existing inframammary folds and the proposed new inframammary fold position. The symmetry of these markings is aided by a vertical-midline “plumb-line” marking, and an intersecting horizontal line passing through the position of the “neo-inframammary fold.” Limits of planned dissection, locations of glandular scoring, and proposed periareolar/circumareolar patterns are marked (Fig. 4). A periareolar incisional approach is used in all cases. Dissection progresses in a perpendicular fashion through the gland directly to the prepectoral fascia. Prefascial dissection is then carried inferiorly to the limits of the premarked new inframammary fold line. Radial scoring of the gland of the inferior dermoglandular flap is performed with electrocautery as demonstrated in Figure 5; the endpoint of this dissection is the appropriate expansion and release

Table 1. Classification of Tuberous Breast Deformities

Type	Base	Inframammary Fold	Skin Envelope	Breast Volume	Ptosis	Areola
I	Minor constriction	Normal laterally, minor elevation medially	Sufficient	Minimal deficiency, no deficiency, or hypertrophy	Mild, moderate, or severe	Enlargement
II	Moderate constriction	Medial and lateral elevation	Inferior insufficiency	Moderate deficiency	None or mild	Normal, mild, or moderate herniation
III	Severe constriction	Elevation of entire fold, or fold absence	Global insufficiency	Severe deficiency	Mild/moderate	Severe herniation

Downloaded from http://journals.lww.com/plasrecon by 2F8RmW0sHs1UJfpmYa5b04sVh/0foqQ05/siQz0qd on 09/24/2024

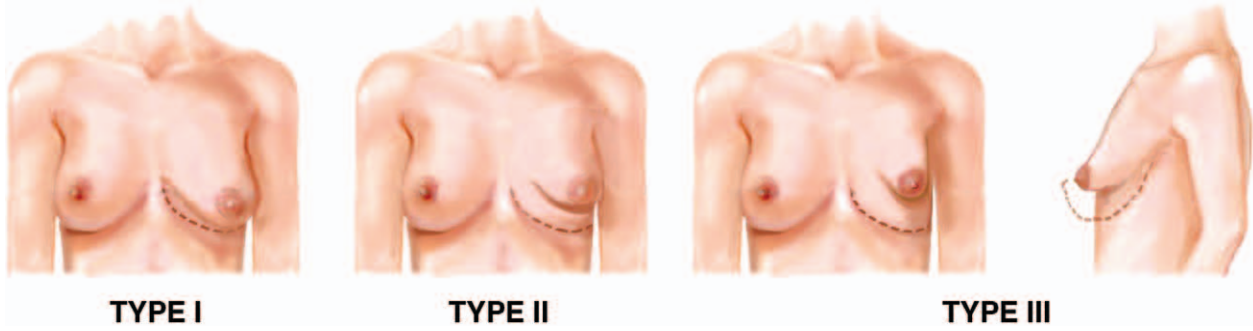


Fig. 1. Classification of tuberous breast deformity. Type I, hypoplasia of the lower medial quadrant; type II, hypoplasia of the lower medial and lateral quadrants; and type III, severe breast constriction and global hypoplasia.

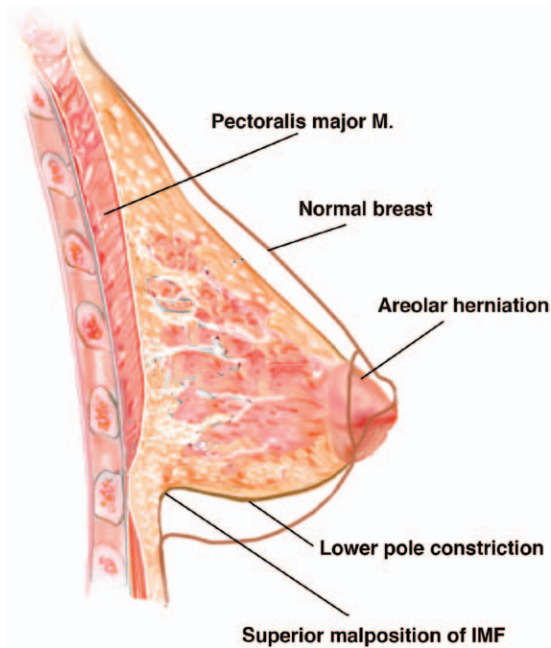


Fig. 2. Anatomical features of tuberous breast deformity. IMF, inframammary fold.

of the lower pole constriction and overcoming the “memory” of the previous inframammary fold line. The pectoralis major muscle is then horizontally incised across its inferior margin, and a retropectoral dissection plane is developed with electrocautery (Fig. 6). Dissection planes are drained with a closed suction drain in all cases. One-stage prosthetic augmentation, or first-stage insertion of a tissue expander, is performed with implants placed in a subpectoral (dual-plane) position.^{7,8} Natrelle Style 10 or 15 smooth, round silicone gel-filled implants (Allergan, Inc., Irvine, Calif.), or Style 68 saline implants (Allergan), are used for all one-stage corrections, and for second-stage expander-to-implant exchanges; Natrelle Style 133MV (Allergan) textured tissue expanders are used in all two-stage corrections. The gland is

then reapproximated in layers. When areolar position, shape, or herniation correction is required, or when breast ptosis correction is required, circumareolar mastopexy is performed with the scoring of concentric circular incisions to include the excess areola, and the intervening areola and skin are deepithelialized. Interlocking purse-string suture with nonabsorbable suture material (CV-3 GoreTex; W. L. Gore and Associates, Inc., Flagstaff, Ariz.) coapts the concentric incision lines and reduces the areolar surface area and projection. When ptosis correction with the circumareolar mastopexy insufficiently improves breast shape and projection, a vertical mastopexy limb is added. Running intradermal absorbable monofilament suture completes the closure. A short video shows the major surgical steps described. (See **Video, Supplemental Digital Content 1**, which demonstrates the operative technique for correction of tuberous breast deformity, <http://links.lww.com/PRS/B170>.)

RESULTS

Patients were followed postoperatively for a mean duration of 22 months (range, 8 to 37 months). Patient demographic information is summarized in Table 2. Twelve type I deformities, 26 type II deformities, and 13 type III deformities were treated. An areolar approach was used in all patients. Radial scoring maneuvers of the gland were performed in all cases. All implants in both one-stage correction (permanent implants) and two-stage correction (tissue expanders followed by permanent implants at exchange) were placed in a subpectoral position. Periareolar incisions (along the inferior border of the areola only) were used in two breasts (4 percent). Circumareolar mastopexy was used in 49 (96 percent), and a vertical mastopexy was used in four (8 percent). One-stage correction was achieved in 47 (92 percent); four

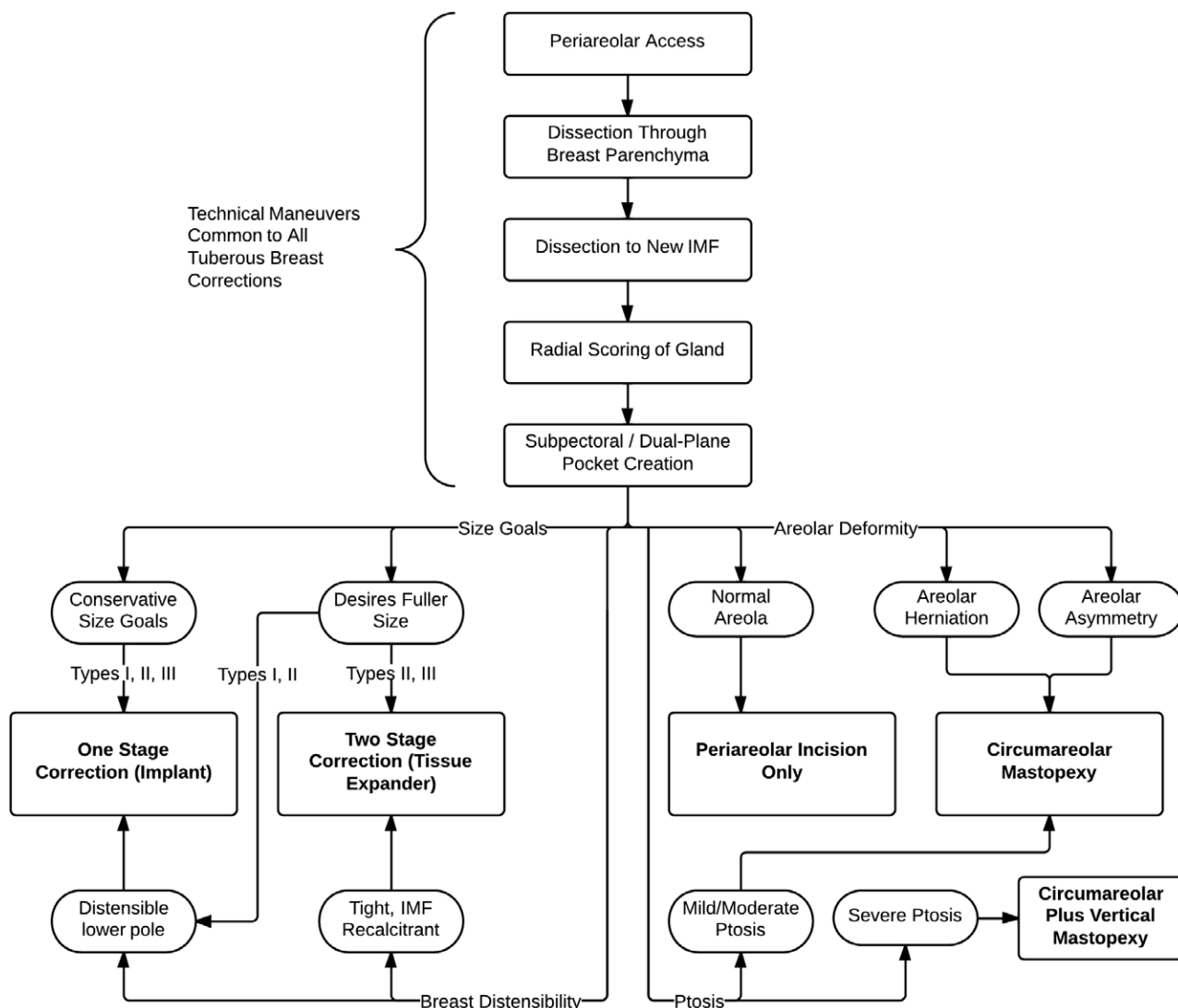


Fig. 3. Treatment algorithm for tuberous breast deformity. *IMF*, inframammary fold.

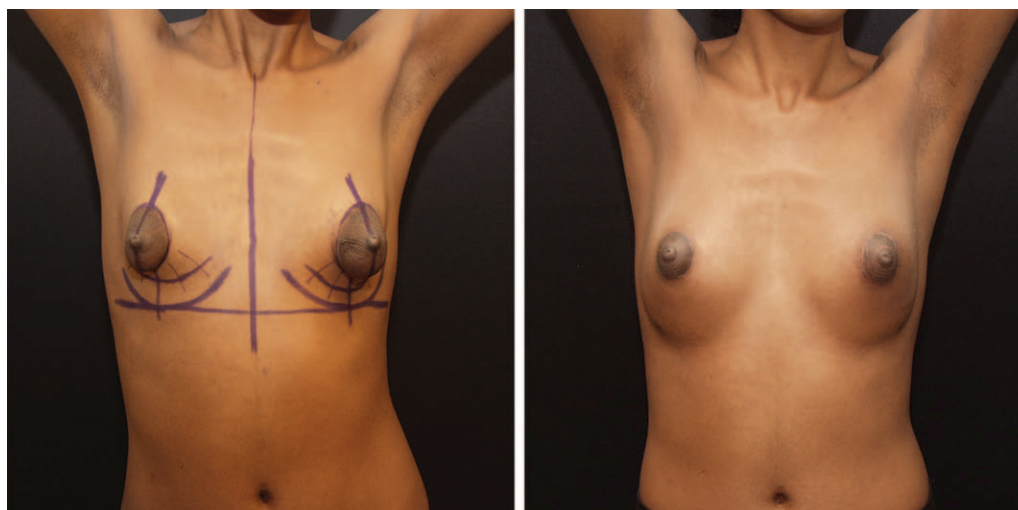

Fig. 4. Preoperative markings for the treatment of tuberous breast deformity (*left*), and 13-month post-operative view (*right*) of single-stage correction of type III tuberous breast deformity.

Downloaded from http://journals.lww.com/plasreconsurg by 2F7RmWm0Shs1UJfpmYas5b04sVh/0foqO05/siCz0qd
 dfIge-INsaw+7ossuHaek853AM3S.RMMMywBzWzWzCGs+zZTdIs/sjvBFoc1lwK88s23yNleuwBmLk2suUQIB0hGOOaKv/0DNIXB
 10nq8bqpfAL/BmImdskzm58HFY = on 09/24/2024

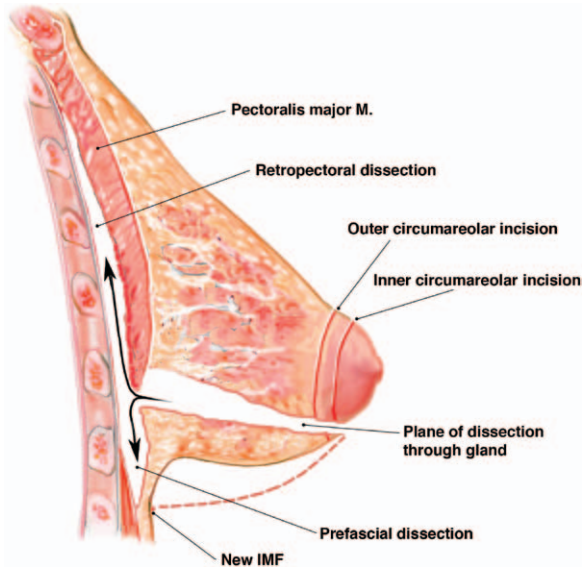


Fig. 5. Illustration of surgical technique for tuberous breast correction, demonstrating the periareolar transglandular approach to the prefascial and retropectoral planes. *IMF*, inframammary fold.

(8 percent) were treated in two stages with tissue expansion. Table 3 further summarizes the distribution of tuberous breast deformity presentation, and Table 4 illustrates the treatment of tuberous breast deformity by type. There were no infections, hematomas, or seromas. The global complication rate for all patients in this study was 7.8 percent:

two breasts (3.9 percent) had Baker grade III capsular contracture, and two (3.9 percent) had malposition. The BREAST-Q postoperative satisfaction with outcome scale mean score was 83 ± 11 . Satisfaction with breasts mean score was 90 ± 11 , psychosocial well-being mean score was 82 ± 14 , and sexual well-being mean score was 79 ± 17 . Overall aesthetic outcomes based on symmetry, breast shape, scar, and overall aesthetic result by blinded scoring were as follows: excellent, 16 patients (62 percent); very good, six patients (23 percent); and good, four patients (15 percent). No patients had poor aesthetic outcomes. Representative patient examples are shown in Figures 7 through 13.

DISCUSSION

The tuberous breast deformity is a congenital breast anomaly that becomes manifest at the time of breast development. Although the exact cause is unclear, it is theorized that the deformity has an embryologic origin,⁹ and its physical manifestations are attributed to a combination of periareolar ring constriction and thin or hypoplastic areolar fascial support.^{2,9-11} Asymmetry is a common hallmark of tuberous breast deformity, with discrepancies seen in both breast volume and shape, areola size, and degree of ptosis.¹²

The first diagnostic dilemma is that tuberous breast deformity in its milder forms is commonly

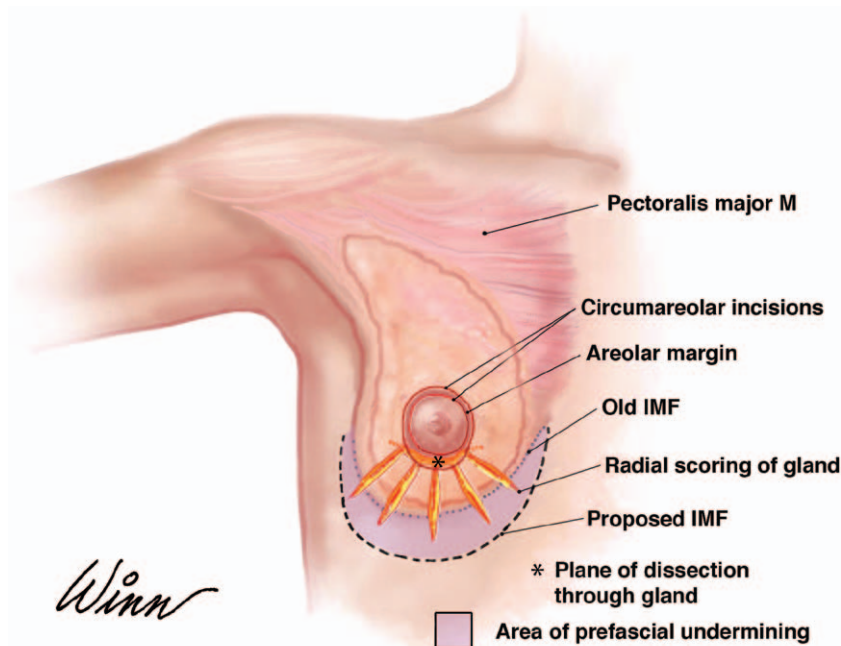
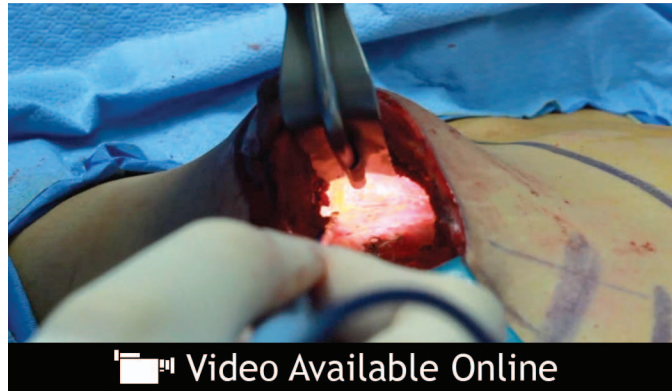

Fig. 6. Illustration of surgical technique for tuberous breast correction, demonstrating radial scoring maneuvers for the release of glandular and native inframammary fold constriction. *IMF*, inframammary fold.



Video. Supplemental Digital Content 1 demonstrates the operative technique for correction of tuberous breast deformity, <http://links.lww.com/PRS/B170>.

Table 2. Tuberous Breast Deformity Study Demographic Information

	Value
No. of patients	26
No. of breasts	51
Age at the time of surgery, yr	
Mean	25
Range	18–39
Follow-up duration, mo	
Mean	22
Range	8–37

Table 3. Presentation of Tuberous Breast Deformity

	Value (%)
Deformity classification, no. of breasts	
Type I	12 (24)
Type II	26 (51)
Type III	13 (25)
Areolar herniation, no. of breasts	47 (92)
Ptosis, no. of breasts	22 (43)
Presentation of deformity, no. of patients	
Unilateral	1 (4)
Bilateral	25 (96)

underappreciated and underdiagnosed. When unrecognized, treating the less obvious variants of the tuberous deformity with more common breast augmentation techniques will often fail to appropriately address the deficiencies and restrictions of the breast lower pole, and may exacerbate areolar herniation, yielding a less pleasing breast shape. Moderate and severe forms of tuberous breast deformity, with more substantial pathologic manifestations, although more obvious, often pose a formidable task for the surgeon. Achievement of consistency in breast reshaping and correcting associated breast asymmetry make the treatment of the tuberous breast deformity one of the greatest technical challenges in aesthetic breast surgery.

Of paramount importance is the choice of incisional access for gaining control of the breast. We have found that the periareolar approach affords the most flexibility and predictability, and use this approach exclusively for the correction of tuberous breast deformities. First, areolar access is superior to an inframammary fold incision because the final location of the inframammary

Table 4. Treatment of Tuberous Breast Deformity by Type

Treatment	Tuberous Breast Classification			Total (%)
	Type I	Type II	Type III	
One- vs. two-stage				
One-stage	12	26	9	47 (92)
Two-stage (tissue expander/implant)	0	0	4	4 (8)
Incision				
Periareolar only	0	2	0	2 (4)
Circumareolar mastopexy	12	24	13	49 (96)
Vertical (in addition to circumareolar mastopexy)	4	0	0	4 (8)

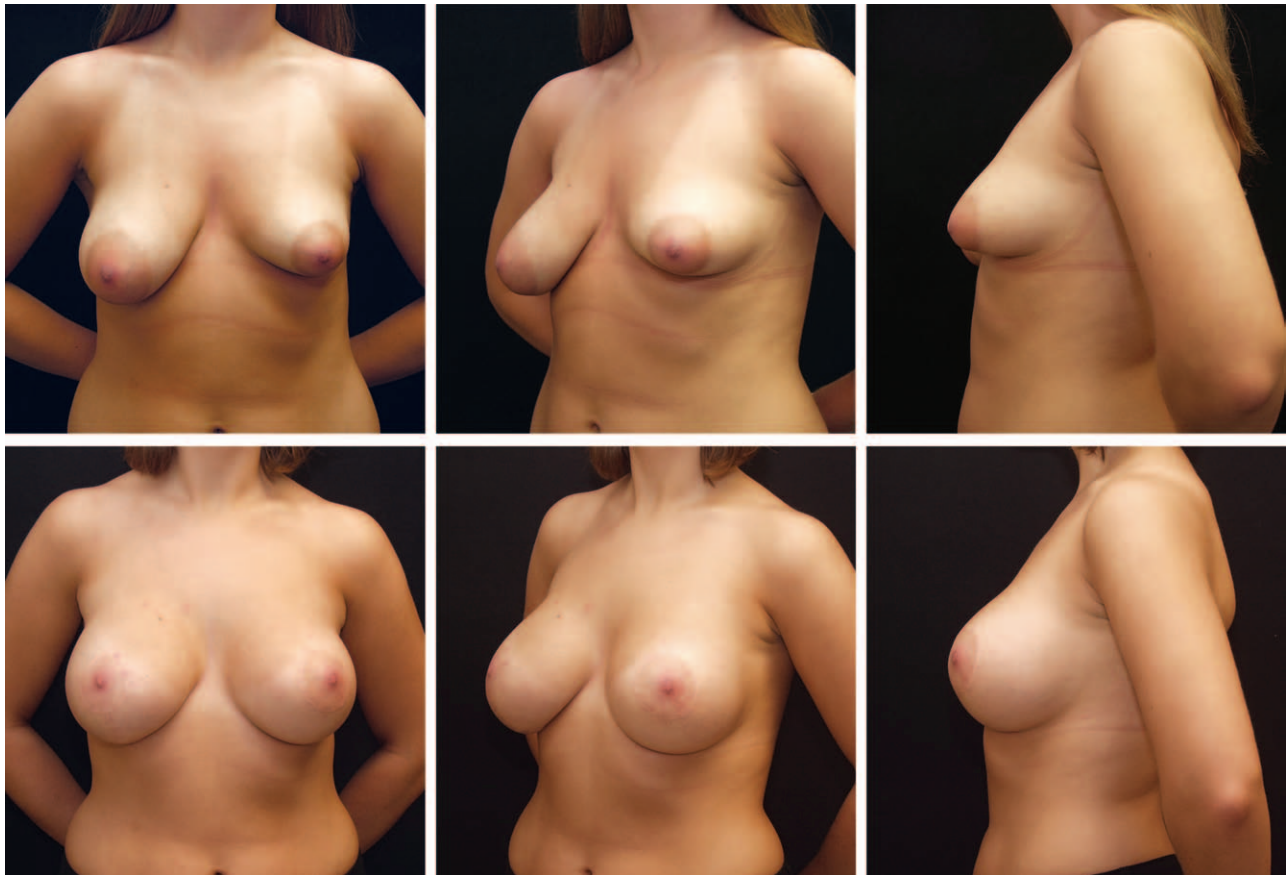

Fig. 7. Tuberous breast correction. (Above) Preoperative views of a 20-year-old patient with right type I tuberous breast deformity and left type II tuberous breast deformity. (Below) Postoperative views of an excellent result at 18 months after one-stage correction with right circumareolar and vertical mastopexy, left circumareolar mastopexy, and placement of Allergan style 10-270 (270 cc) (right breast) and 15-371 (371 cc) (left breast) silicone smooth round implants.

fold is extremely difficult to determine precisely, obviating an inframammary scar that is superiorly or inferiorly malpositioned. In addition, the areolar approach also affords access to a dissection plane directly through the subareolar breast parenchyma, effectively releasing any internal glandular ring constriction that may exist with the deformity. Finally, any areolar positional asymmetries, shape abnormalities, and herniation are readily adjustable by means of the areolar approach, making this the ideal access site for tuberous breast correction.

The release of glandular and breast base constriction with radial scoring maneuvers is used in every case.^{13,14} After dissecting through the gland to the prepectoral fascial plane, dissection is further developed inferiorly to the proposed new limit of the breast lower pole. Care must be exercised not to undermine this line; it is simple to adjust inferiorly if necessary and considerably more difficult and time consuming to reestablish if undermined. This initial prepectoral dissection also serves as

the first component of the dual-plane dissection. With the deep surface of the gland exposed, electrocautery scoring of the gland is performed. The constricting horizontally oriented fascial bands within the gland and along the preexisting inframammary fold are incised in a perpendicular (vertical/radial) fashion from the deep subglandular plane, progressing superficially to the point of release. The periareolar transglandular approach is ideal for facilitating the exposure to this lower pole subglandular plane, and for radially dividing the fascial constriction. The extent and depth of scoring is predicated on the degree of constriction, and the endpoint is the expansion of the breast lower pole and the visual release of any preexisting, native inframammary fold memory. In cases of more severe soft-tissue and native fold constriction, the radial scoring maneuvers can be carried to the subdermal plane if necessary.

From the earliest reports of tuberous breast deformity correction, and prevailing today, the placement of an implant in the subglandular

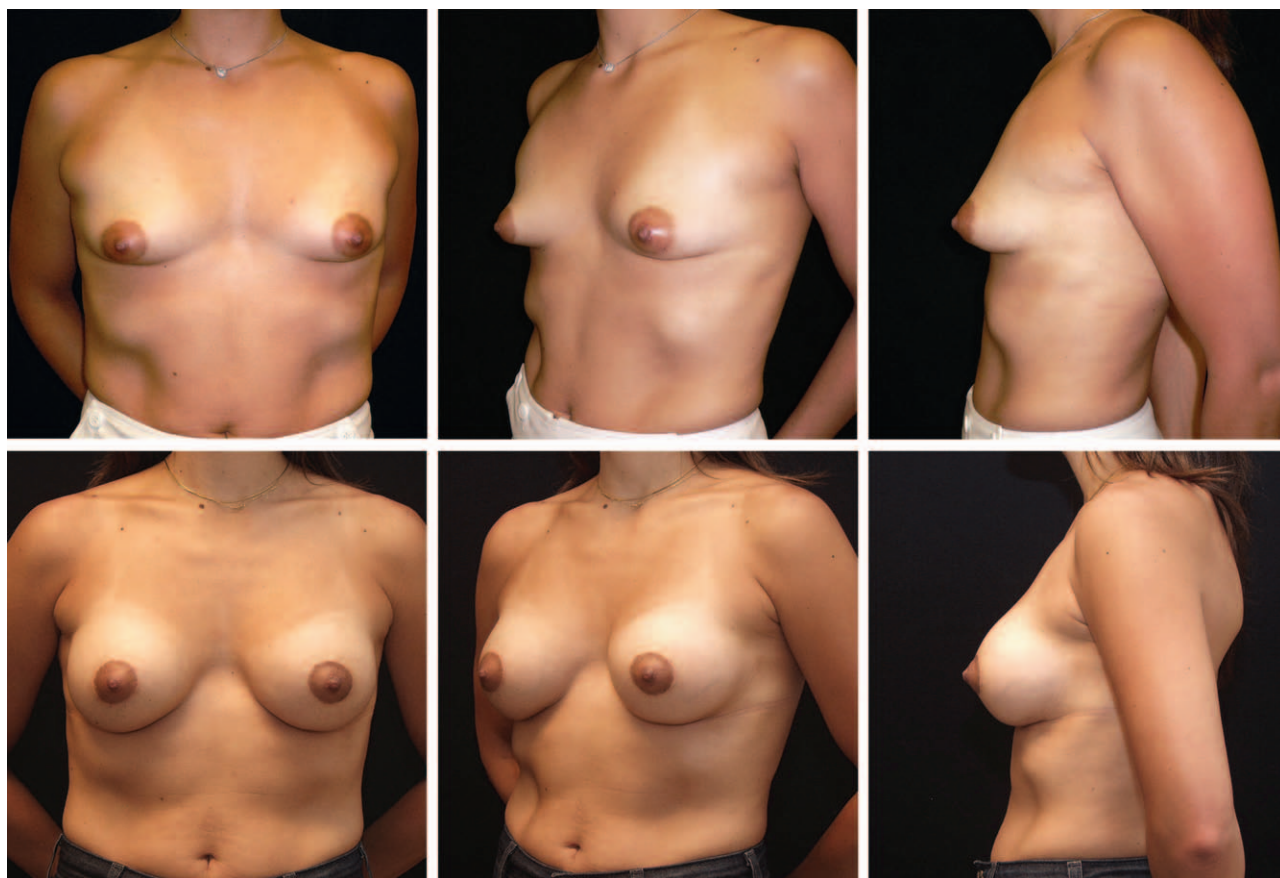


Fig. 8. Tuberosus breast correction. (Above) Preoperative views of a 35-year-old patient with bilateral type II tuberous breast deformity. (Below) Postoperative views of an excellent result at 15 months after one-stage correction with circumareolar mastopexy and placement of Allergan 68MP-270 saline smooth round implants filled to 295 cc.

space has been advocated.^{9,10,13–15} The advantage of subglandular placement relates to the ability of the prosthesis to shape and expand the breast without being restricted by the pectoralis major muscle. The many negative sequelae of subglandular implants, including increased contracture rates, visible implant margins and rippling, late malposition, and unnatural breast appearance,^{16–20} become manifest in tuberous breast correction following the necessary scoring and thinning of the parenchyma. With further understanding of dual-plane augmentation,^{7,8,21} it becomes clear that to varying degrees all subpectoral breast augmentations are dual-plane by definition, with the implant in the breast lower pole effectively subglandular and that in the upper pole submuscular. Because the lower pole is the region of the breast in tuberous deformities that requires the most “expansion” and implant-related shape definition, with little need for more aggressive fill and expansion of the upper pole, dual-plane submuscular augmentation is ideal. Dual-plane maneuvers also

encourage the inferior incised margin of the muscle to shift superiorly, away from the region of the released native inframammary fold. The result is an unchecked fill of the lower pole and promotion of the many advantages of submuscular augmentation, including softer, more natural contour of the upper pole, increased soft-tissue coverage, more durable breast position, and decreased capsular contracture rates.^{16–19,22}

Breast size asymmetry is adjusted with the selection of different implant volume, projection, or both, and/or by the removal of excess gland from the larger breast. We prefer the latter approach, as it affords the opportunity to remove a saucer or wedge of parenchyma from the deepest aspect of the subareolar gland (which may minimize the herniation), and keeps the implant sizes more similar, theoretically contributing to longer term durability of results.

Correction in one stage is achieved in the majority of cases. When deficient lower pole skin and soft tissue is distensible, and particularly when size goals are conservative, single-stage

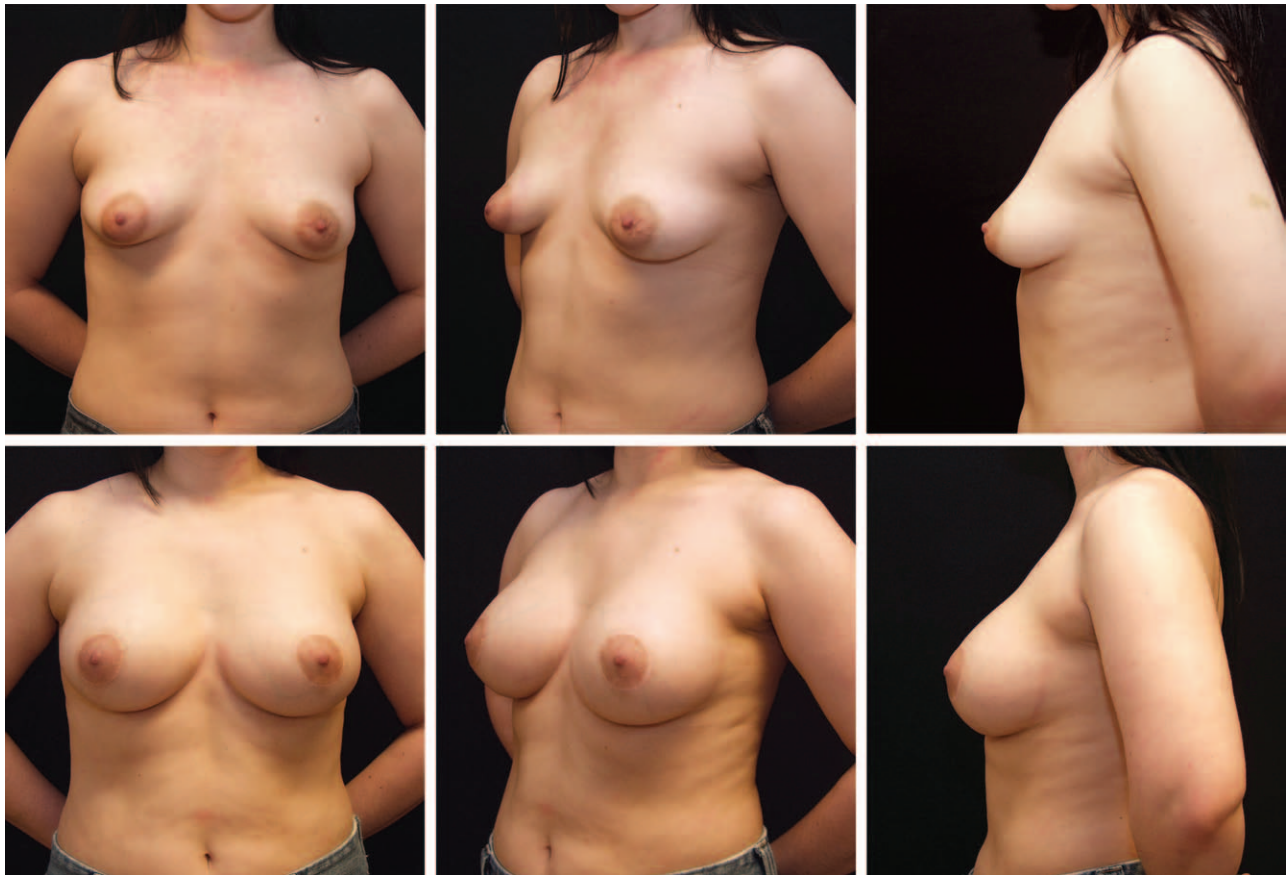

Fig. 9. Tuberous breast correction. (Above) Preoperative views of a 32-year-old patient with bilateral type II tuberous breast deformity. (Below) Postoperative views of an excellent result at 12 months after one-stage correction with circumareolar mastopexy and placement of Allergan style 15-371 (371 cc) silicone smooth round implants.

correction is most often attainable. In cases of moderate and severe breast hypoplasia (types II and III) where the patient desires a fuller result than the deficient lower pole skin and soft tissue will allow in one stage, or when the preexisting inframammary fold memory cannot be overcome, two-stage correction with tissue expander placement is advisable. In circumstances where there is severe constriction of the skin envelope and a superiorly malpositioned inframammary fold that is likely to be difficult to overcome with intraoperative maneuvers in one stage, two-stage correction with primary insertion of tissue expanders is recommended. In addition, two-stage correction can provide for a planned return for a “second look,” enabling adjustments in areolar position and shape, and fine-tuning of breast symmetry.

Breast ptosis requires clear identification in every case when formulating a treatment plan. We have found that more classical grading of breast ptosis (grade I, II, and III, and pseudoptosis)²³ does not adequately aid in the description

and treatment planning of tuberous ptosis. With inframammary crease malposition; deficiency of lower pole skin and soft tissue; and frequent enlargement, malposition, and herniation of the areola, we commonly see relative glandular hypertrophy and breast ptosis that defy standard classification. With the areolar position well below the preexisting inframammary fold, suggesting a grade II or III ptosis, the nipple-to-inframammary fold distance is often quite short in tuberous breast deformity. Whereas short-scar, circumvertical mastopexy incisions or extended incisions may be required for nontuberous moderate and high-grade ptosis, more limited incisions are often sufficient in tuberous ptosis. After the often-necessary maneuvers to lower the inframammary fold and recruit and expand the lower pole, the “lift” of the breast and areola can often be adequately managed with a circumareolar incision. We find that vertical and extended mastopexy incisions in the lower pole are most efficacious in nontuberous ptotic breasts for increasing projection; the opposite is true in

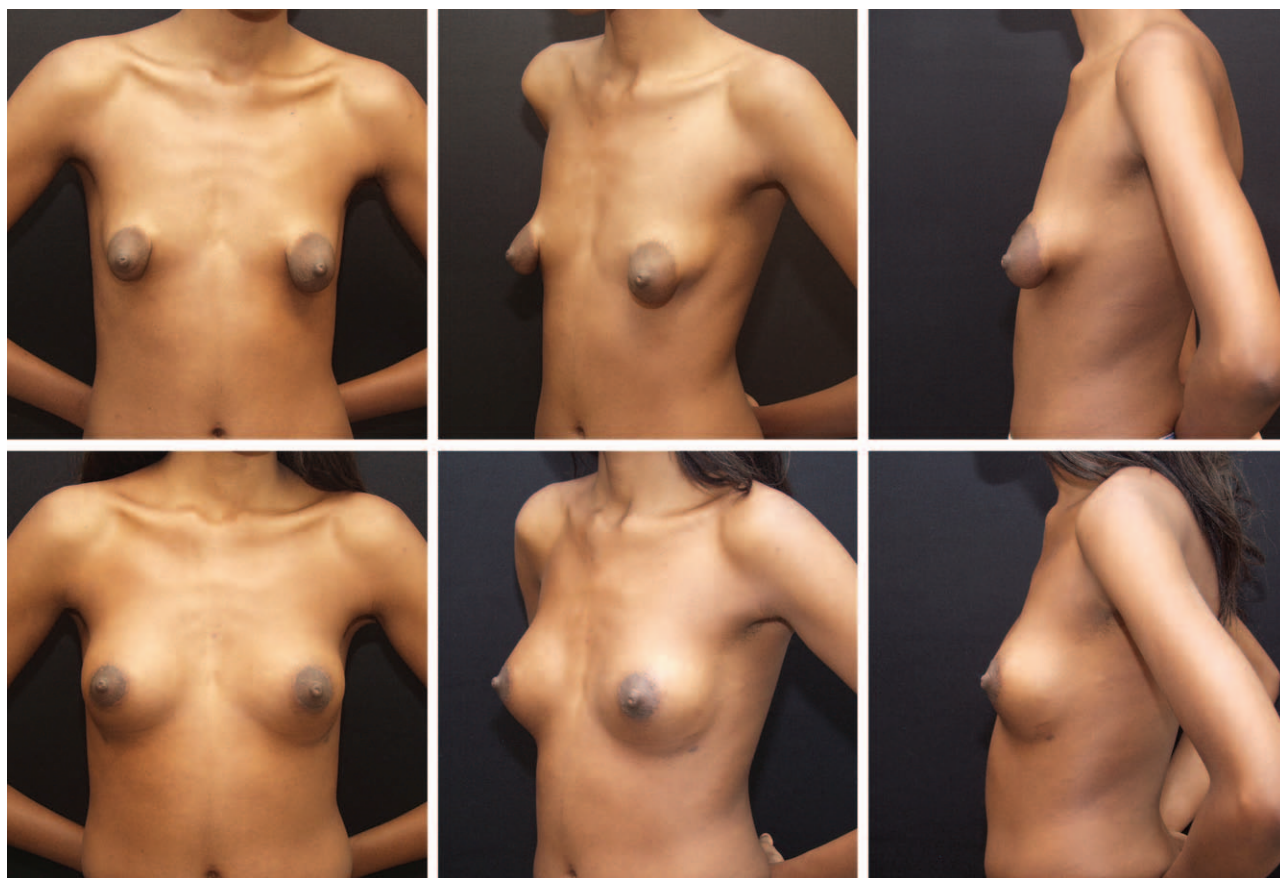

Fig. 10. Tuberosus breast correction. (Above) Preoperative views of a 29-year-old patient with bilateral type III tuberous breast deformity. (Below) Postoperative views of an excellent result at 13 months after one-stage correction with circum-areolar mastopexy and placement of Allergan style 10-210 (210 cc) (right breast) and 10-180 (180 cc) (left breast) silicone smooth round implants. Despite hypoplasia in all four quadrants and severe constriction, satisfactory correction was achieved in one stage.

tuberous ptosis, where the ptotic breast that overhangs a superiorly displaced fold is usually too projected. In cases where considerable breast skin excess remains, or when increased projection is required, a vertical incision can be added and tailored intraoperatively, and “made to measure” as needed.

Round-block suture technique has been described for both circumareolar mastopexy and for reducing areolar diameter and projection.^{15,24} We have used the interlocking purse-string suture technique²⁵ that has promoted consistency in areolar diameter and excellent correction by a more uniform flattening of the areolar projection. When areolar herniation and deformity are identified, the selection of a circumferential approach, as opposed to a periareolar incision only, is warranted. In mild forms of tuberous breast deformity without areolar herniation, provided that lower pole expansion maneuvers (constriction release, radial scoring)

are performed, theoretically, any breast incision, including inframammary fold access, that facilitates these exercises is appropriate. Nevertheless, because of the unpredictable nature of the final position of the inframammary fold after the postoperative lower pole expansion, and the outstanding exposure and control of breast parenchyma afforded by the areolar approach, we favor the latter access for all cases of tuberous breast correction.

Despite accounts of breast glandular division and transposition,^{2,26–28} we feel that the amount of breast parenchyma is often diminutive, and have found only rare circumstances with enough autologous breast tissue to satisfactorily augment the hypoplastic lower pole or to sufficiently fortify or cover a breast implant. Thus, we do not espouse parenchymal flap transposition techniques. Furthermore, Panchapakesan and Brown¹⁴ have described the use of anatomical, form-stable, highly cohesive silicone gel

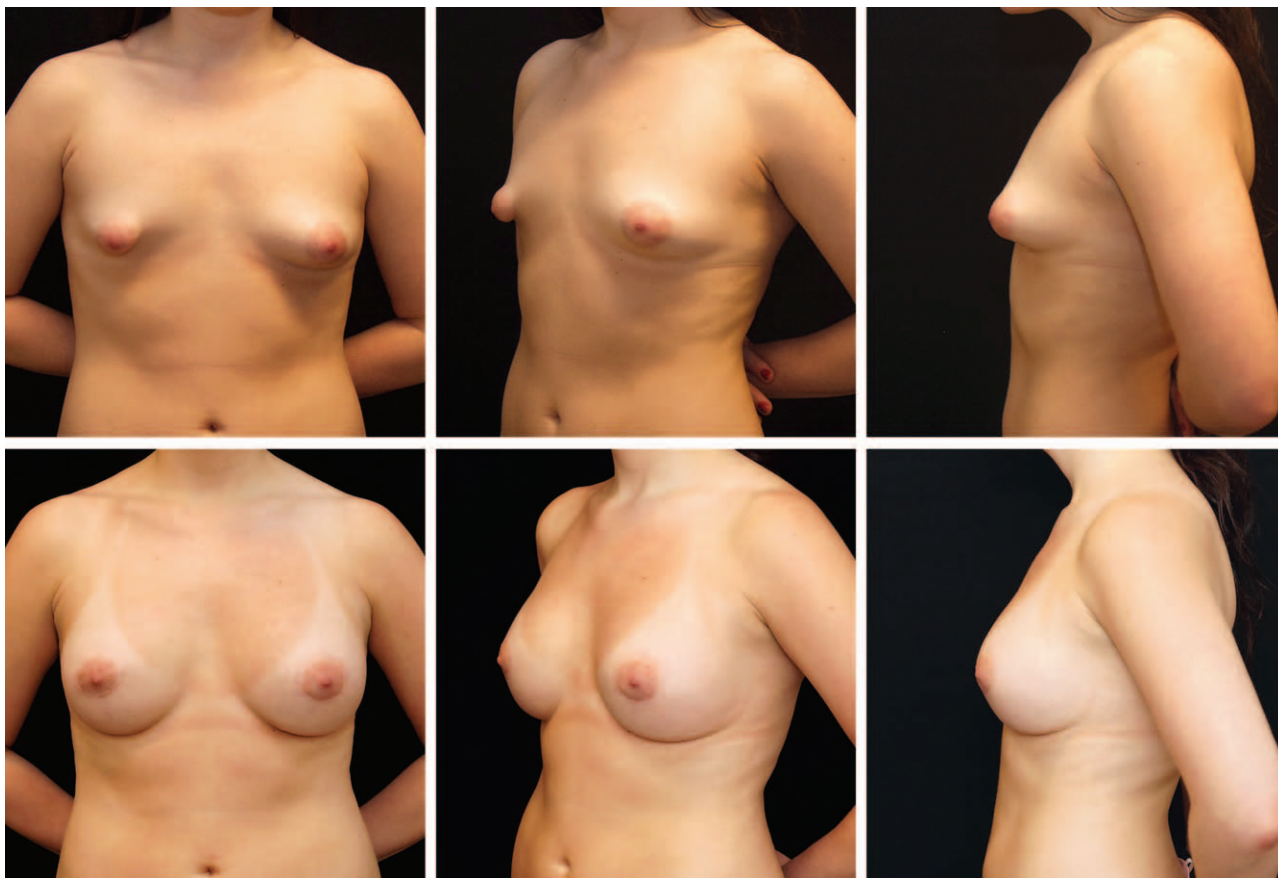


Fig. 11. Tuberosus breast correction. (Above) Preoperative views of a 27-year-old patient with right type III tuberous breast deformity and left type II tuberous breast deformity. (Below) Postoperative views of an excellent result at 16 and 21 months after two-stage correction with bilateral circumareolar mastopexy. Given the patient's desire for a fuller result, Allergan style 133 MV-12 300-cc tissue expanders (width, 12.0 cm; height, 11.0 cm; projection, 5.2 cm) were placed during the first procedure and were sequentially filled to 410 cc bilaterally. Tissue expanders were exchanged with Allergan style 15-339 silicone smooth round implants after 5 months at the second stage.

implants for the correction of tuberous breast deformities, with good results. These firmer anatomical implants may confer a theoretical advantage of exerting more direct force on the breast base and lower pole and maximizing the stretch of the tissues,¹⁴ with a low incidence of rippling and capsular contracture.²⁹ Although we have uniformly used smooth, round implants in this study with very favorable results, the use of anatomical highly cohesive gel implants should be considered.

The global complication rate was 7.8 percent, with capsular contracture in two breasts (3.9 percent) and malposition in two breasts (3.9 percent). All cases were in type II tuberous breast deformities, and each had been treated primarily with subpectoral augmentation with smooth round silicone gel implants in one stage with a circumareolar mastopexy incision. Capsular contracture development was noted at 4 months and

6 months, respectively; one patient was pleased with her overall result, and did not seek correction, and one patient (one breast) elected reoperation for capsular contracture, which was treated successfully with total capsulectomy and implant exchange with a textured, round gel implant. Both positional deformities were inferior malpositions; each was considered mild by both patient and surgeon. Both patients were pleased with their overall results, and neither sought correction. Furthermore, although the mean follow-up period was 22 months (range, 8 to 37 months), this is considered moderate-term follow-up. There are no clear data in the literature that address the time to capsular contracture development; therefore, this period might not be sufficient to capture all cases of late capsular contracture, asymmetry, or deformity development. It is conceivable that deformities may emerge over the longer term, and the possibility




Fig. 12. Tuberos breast correction. (Above) Preoperative views of an 18-year-old patient with right type I tuberous breast deformity and left type II tuberous breast deformity. (Below) Postoperative views of a very good result at 24 months after one-stage correction with bilateral circumareolar mastopexy and placement of Allergan saline smooth round implants, 68MP-225 filled to 295 cc (right breast) and 68LP-300 filled to 320 (left breast).

of late development of complications should be considered.

There are several limitations to this investigation. Whereas the postoperative results, patient satisfaction, and reproducibility of this treatment strategy are encouraging, this is a single-surgeon, retrospective review of 51 breasts in 26 patients; therefore, direct inferences cannot necessarily be made from our study sample to a larger population. Nevertheless, the favorable results support the consideration and potential use of this approach in patients with tuberous breast deformity. We believe that further studies may be helpful in supporting the findings of this study. Finally, postoperative assessment with the BREAST-Q score demonstrated high patient psychosocial well-being, sexual well-being, satisfaction with breasts, and satisfaction with overall outcome. Preoperative BREAST-Q modules had not been obtained before commencement of this retrospective study; the authors elected not to request patients' completion of the preoperative questionnaire retrospectively, as the likelihood of

recall bias would be high. Future study that assesses quality-of-life parameters both preoperatively and (at one or several times) postoperatively would add value to quality-of-life outcomes assessment following tuberous breast correction.

CONCLUSIONS

The multiple pathologic hallmarks of breast parenchymal hypoplasia, constriction, skin deficiency, areolar herniation, and ptosis in tuberous breast deformity require careful identification and classification, after which a treatment plan can be defined and followed. This classification and treatment strategy should be considered to help achieve both safety and consistency in aesthetic results in the treatment of the varied forms of tuberous breast deformity.

Adam R. Kolker, M.D.
710 Park Avenue
New York, N.Y. 10021
adam@kolkermd.com

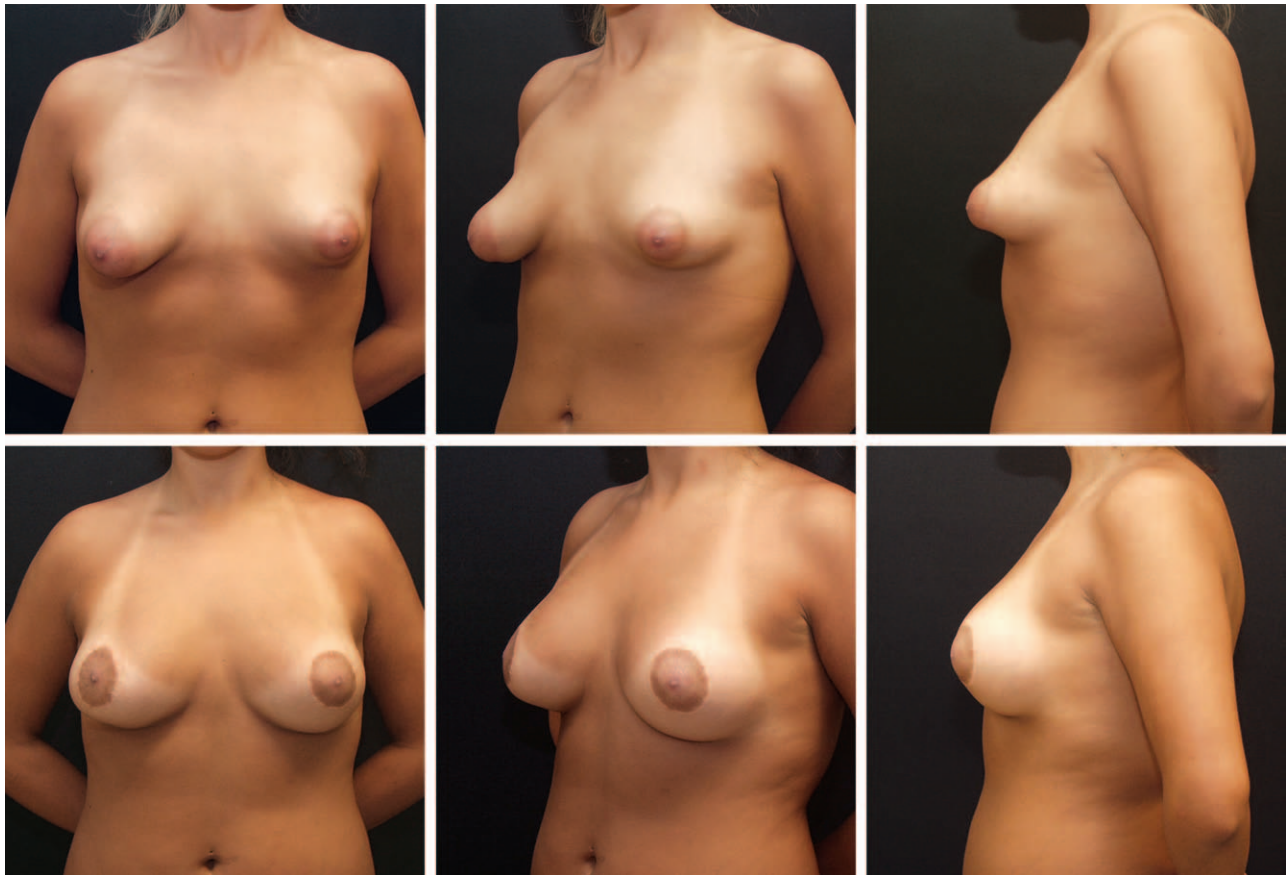

Fig. 13. Tuberous breast correction. (Above) Preoperative views of a 22-year-old patient with bilateral type II tuberous breast deformity. (Below) Postoperative views of a good result at 18 months after one-stage correction with bilateral circumareolar mastopexy and placement of Allergan style 15-304 (304 cc) (right breast) and 15-339 (339 cc) (left breast) silicone smooth round implants.

ACKNOWLEDGMENT

The authors thank John G. Meara, M.D., D.M.D., and Anthony D. Holmes, F.R.A.C.S., for insight and valuable comments during the preparation of this article.

REFERENCES

1. von Heimburg D, Exner K, Kruft S, Lemperle G. The tuberous breast deformity: Classification and treatment. *Br J Plast Surg*. 1996;49:339–345.
2. Grolleau JL, Lanfrey E, Lavigne B, Chavoin JP, Costagliola M. Breast base anomalies: Treatment strategy for tuberous breasts, minor deformities, and asymmetry. *Plast Reconstr Surg*. 1999;104:2040–2048.
3. Costagliola M, Atiyeh B, Rampillon F. Tuberous breast: Revised classification and a new hypothesis for its development. *Aesthetic Plast Surg*. 2013;37:896–903.
4. Meara JG, Kolker A, Bartlett G, Theile R, Mutimer K, Holmes AD. Tuberous breast deformity: Principles and practice. *Ann Plast Surg*. 2000;45:607–611.
5. Pusic AL, Klassen AF, Scott AM, Klok JA, Cordeiro PG, Cano SJ. Development of a new patient-reported outcome measure for breast surgery: The BREAST-Q. *Plast Reconstr Surg*. 2009;124:345–353.
6. Memorial Sloan Kettering Cancer Center. The BREAST-Q. Available at: <http://www.breast-q.org>. Accessed February 15, 2014.
7. Tebbetts JB. Dual plane breast augmentation: Optimizing implant-soft-tissue relationships in a wide range of breast types. *Plast Reconstr Surg*. 2001;107:1255–1272.
8. Tebbetts JB. Dual plane breast augmentation: Optimizing implant-soft-tissue relationships in a wide range of breast types. *Plast Reconstr Surg*. 2006;118(Suppl):81S–98S; discussion 99S–102S.
9. Mandrekas AD, Zambacos CJ, Anastasopoulos A, Hapsas D, Lambrinaki N, Ioannidou-Mouzaka L. Aesthetic reconstruction of the tuberous breast deformity. *Plast Reconstr Surg*. 2003;112:1099–1108; discussion 1109.
10. Pacifico MD, Kang NV. The tuberous breast revisited. *J Plast Reconstr Aesthet Surg*. 2007;60:455–464.
11. Mandrekas AD, Zambacos CJ. Aesthetic reconstruction of the tuberous breast deformity: A 10-year experience. *Aesthet Surg J*. 2010;30:680–692.
12. DeLuca-Pytell DM, Piazza RC, Holding JC, Snyder N, Hunsicker LM, Phillips LG. The incidence of tuberous breast deformity in asymmetric and symmetric mammoplasty patients. *Plast Reconstr Surg*. 2005;116:1894–1899; discussion 1900.
13. Rees TD, Aston SJ. The tuberous breast. *Clin Plast Surg*. 1976;3:339–347.
14. Panchapakesan V, Brown MH. Management of tuberous breast deformity with anatomic cohesive silicone gel breast implants. *Aesthetic Plast Surg*. 2009;33:49–53.
15. Atiyeh BS, Hashim HA, El-Douaihy Y, Kayle DI. Perinipple round-block technique for correction of tuberous/tubular breast deformity. *Aesthetic Plast Surg*. 1998;22:284–288.

16. Stevens WG, Nahabedian MY, Calobrace MB, et al. Risk factor analysis for capsular contracture: A 5-year Sientra study analysis using round, smooth, and textured implants for breast augmentation. *Plast Reconstr Surg*. 2013;132:1115–1123.
17. Vazquez B, Given KS, Houston GC. Breast augmentation: A review of subglandular and submuscular implantation. *Aesthetic Plast Surg*. 1987;11:101–105.
18. Henriksen TF, Fryzek JP, Hölmich LR, et al. Surgical intervention and capsular contracture after breast augmentation: A prospective study of risk factors. *Ann Plast Surg*. 2005;54:343–351.
19. Biggs TM, Yarish RS. Augmentation mammoplasty: A comparative analysis. *Plast Reconstr Surg*. 1990;85:368–372.
20. Codner MA, Mejia JD, Locke MB, et al. A 15-year experience with primary breast augmentation. *Plast Reconstr Surg*. 2011;127:1300–1310.
21. Spear SL, Carter ME, Ganz JC. The correction of capsular contracture by conversion to “dual-plane” positioning: Technique and outcomes. *Plast Reconstr Surg*. 2003;112:456–466.
22. Blount AL, Martin MD, Lineberry KD, et al. Capsular contracture rate in a low-risk population after primary augmentation mammoplasty. *Aesthet Surg J*. 2013;33:516–521.
23. Regnault P. Breast ptosis: Definition and treatment. *Clin Plast Surg*. 1976;3:193–203.
24. Benelli L. A new periareolar mammoplasty: The “round block” technique. *Aesthetic Plast Surg*. 1990;14:93–100.
25. Hammond DC, Khuthaila DK, Kim J. The interlocking Gore-Tex suture for control of areolar diameter and shape. *Plast Reconstr Surg*. 2007;119:804–809.
26. Puckett CL, Concannon MJ. Augmenting the narrow-based breast: The unfurling technique to prevent the double-bubble deformity. *Aesthetic Plast Surg*. 1990;14:15–19.
27. Serra-Renom JM, Muñoz-Olmo J, Serra-Mestre JM. Treatment of grade 3 tuberous breasts with Puckett’s technique (modified) and fat grafting to correct the constricting ring. *Aesthetic Plast Surg*. 2011;35:773–781.
28. Ribeiro L, Canzi W, Buss A Jr, Accorsi A Jr. Tuberous breast: A new approach. *Plast Reconstr Surg*. 1998;101:42–50; discussion 51.
29. Brown MH, Shenker R, Silver SA. Cohesive silicone gel breast implants in aesthetic and reconstructive breast surgery. *Plast Reconstr Surg*. 2005;116:768–779; discussion 780.

Baker Gordon Videos



Baker Gordon
Educational Symposium

PRS proudly presents select lectures and procedural videos from the 2010 Baker Gordon Symposium. To begin watching the Masters at work in our first two entries, visit the [Baker Gordon Video Collection](#).

Now Available!

View Baker Gordon Videos at PRSJournal.com